Cover.docx

1- 1 Page One.docx

2- 1 List of Contents.docx

2- 2 Introduction.docx

3- Introduction To Imaging Modalites.docx

4- CNS Imaging.docx

5- Chest Imaging.docx

6- Cardiac Imaging.docx

7- GIT Imaging.docx

8- UT Imaging.docx

9- Emergency Imaging.docx

10 - Interventional.docx

11- Spot Cases Atlas.docx

12- Sources & References.docx

Basics of

Diagnostic Imaging

MADE EASY FOR MEDICAL STUDENT

BY

Dr. Ahmad Mokhtar Abodahab – MD

Lecturer of Radiology - Faculty of Medicine

Sohag University

2 0 2 2

About Editor:

Dr. Ahmad Mokhtar Abodahab – MD

Lecturer of Radiology –Faculty of Medicine – Sohag University

PACS & Teleradiology Unit Administrator Admin – Sohag Univ. Hospital

Speaker at Virtual Medical Academy , KSA

Radiology Consultant Sohag Military Hospital & Sohag Police Clinics

PACS & Teleradiology Expert & Trainer – Telemedicine Tec. Co , KSA

Certified Trainer - Supreme council of Universities, Egypt

List of Contents

✓ List of contents	2
✓ Introduction	3
✓ Introduction To Imaging Modalities	4
✓ Basics of CNS Imaging	25
✓ Basics of Chest Imaging	36
✓ Basics of Cardiac Imaging	53
✓ Basics of GIT Imaging	66
✓ Basics of UT Imaging	80
✓ Basics of Emergency Imaging	93
✓ Basics of Interventional Radiology	103
✓ Cases Atlas	110
✓ References & Sources	116

.All copyrights © of illustrations printed in this book is reserved to their authors

Introduction

Medical imaging is a very important & common diagnostic tool for most of diseases, many modalities are used, but every modality has its advantages, limitations & hazards also. So any doctor must understand the basics of these modalities, hazards & how to choose the suitable one.

I must be understood,,,,,, so I try to make it easy for all of you.

My best wishes

A.M. Abodahab – MD

Nov 2021

NB. This book is published online in PDF

For Free

for All Medical Student

Introduction to Imaging Modalities

List of Imaging Modalities

- ✓ **X ray**
- ✓ **Ultrasonography & Doppler**
- ✓ **Computed Tomography (CT)**
- ✓ **Magnetic Resonance Imaging (MRI)**
- ✓ **Radio-isotope scan**
- ✓ **…….. & Others**

In Every modality you will study the following:

- Basics of work
- Energy used
- Main Indications
- Contraindications
- Finding of main Pathologies

✍ **Please, don't request any imaging modality for any patient unless you know the value of it for diagnosis of the case.**

X – Ray

Historical Hints :

- ✓ The oldest imaging modality
- ✓ Discovered by **William Rontegen** at 1895
- ✓ The first X ray film was done for Rontegens' wife hand.



Wilhelm Conrad Röntgen

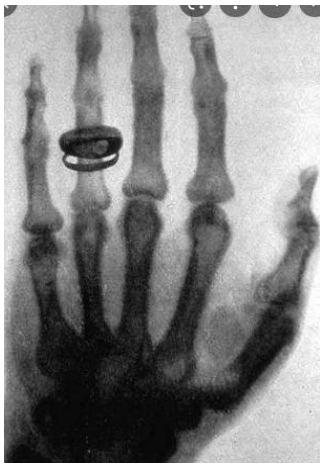

1st X ray Film

X Ray machine

Basics of Work :

- **Energy used** : **X ray** , an ionizing radiation
- **X ray** is from its source (X ray tube) is penetrating objects & images are formed on film.
- **Bright object,** which absorb X ray & prevent it from reaching Film is described as **Radiopaque** (eg. Bone , metals, barium, stones …..etc)
- **Dark object,** which permeate X ray & passing it to Film is described as **Radiolucent** (eg. lung , air……etc)

In this Normal chest X ray (CXR) , Identify:

Radioaque & Radiolucent structures

Bone is Radiopaque

Lungs are Radiolucent

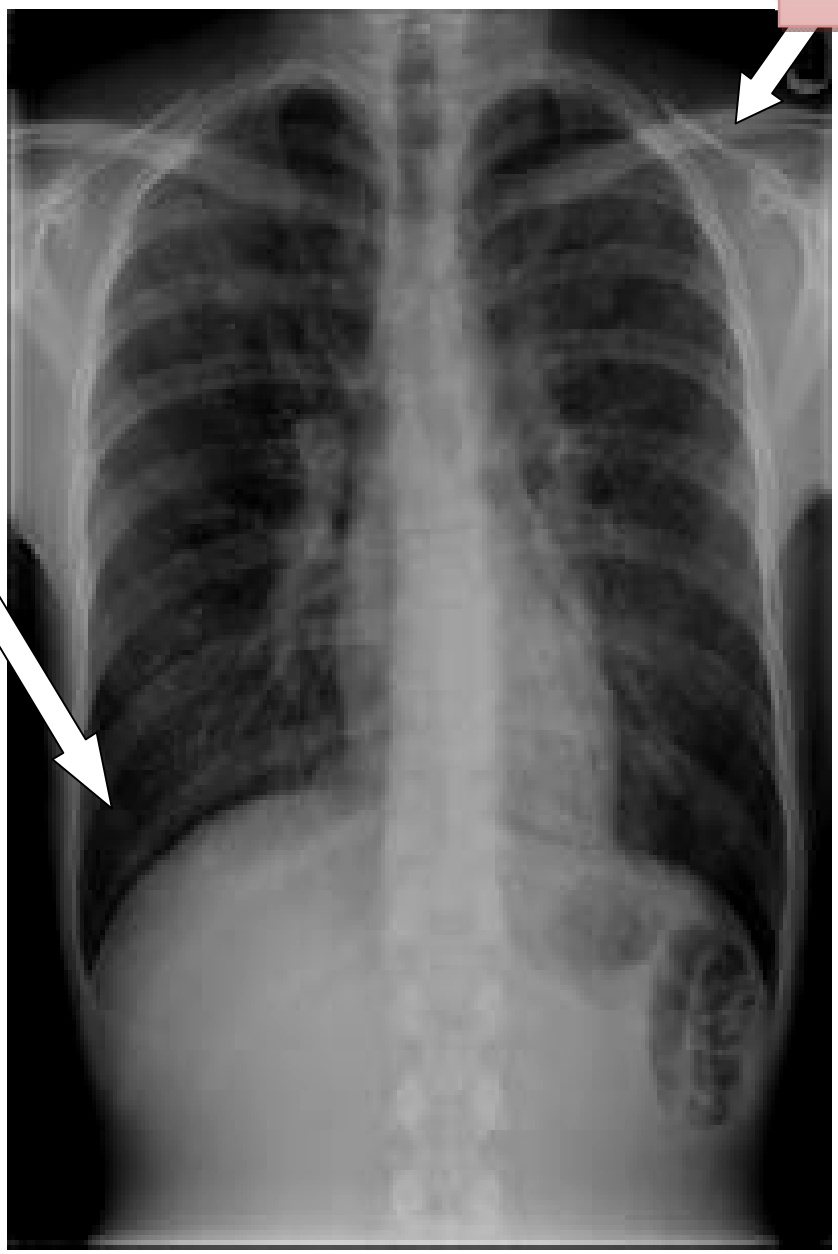

Contraindications :

- **Pregnancy**

  (Especially, early) , it can lead to **teratogenicity**.

- **Non indicated diagnosis ,**

  As you will expose patient to radiation without any benefit .

- **Contrast Hypersensitivity:** for X ray techniques using IV contrast as IVU.

Indications :

X ray is a common used modality, & has many indications, such as diagnosis of:

- ✓ Fractures
- ✓ Foreign body inhalation or ingestion
- ✓ Basic Chest imaging
- ✓ Intestinal obstruction
- ✓ **Bone Tumors**
- ✓ Breast Imaging (Mammography)
- ✓ Urinary stones
- ✓ Perforated Gut

➲ **X ray techniques with Contrast** , as :

- **Barium studies** , for GIT (Barium Swallow, meal, enema)
- **IVU** (Intra venous Urography)
- **Vascular Imaging** (Angiography / Venography)
- T Tube Cholangiogram & Fistulograms

Ionizing Radiation = radiation that cause ionization of atoms exposed to it , so it has **hazards** on different organs espicially with higher doses of radiation & sensetive organs.

Don't Forget

. **X ray is mandatory** for diagnosis of any **Bone tumor**, even with using CT & MRI.

Portable X ray

Mammography

Ultrasonography (US)

Commonest used modality in daily work

Historical Hints :

- The source of Idea of medical ultrasound is naval RADAR.
- Naturally, bats & dolphins are depending in US in hunting.

Basics of Work :

- **Energy used** : Ultrasound (US) ,
- Ultrasound = Sound of frequency > 20.000 Hertz
- US waves are librated from probe (transducer) , penetrating patient tissues , reflected again

Reporting terms:

- **Bright structures** = **Echogenic** or **Hyperechoic** (eg. Stones,fat)
- **Gray structures** = **Hypoechoic**
- **Dark Structures** = **Anechoic** (eg. Fluids)

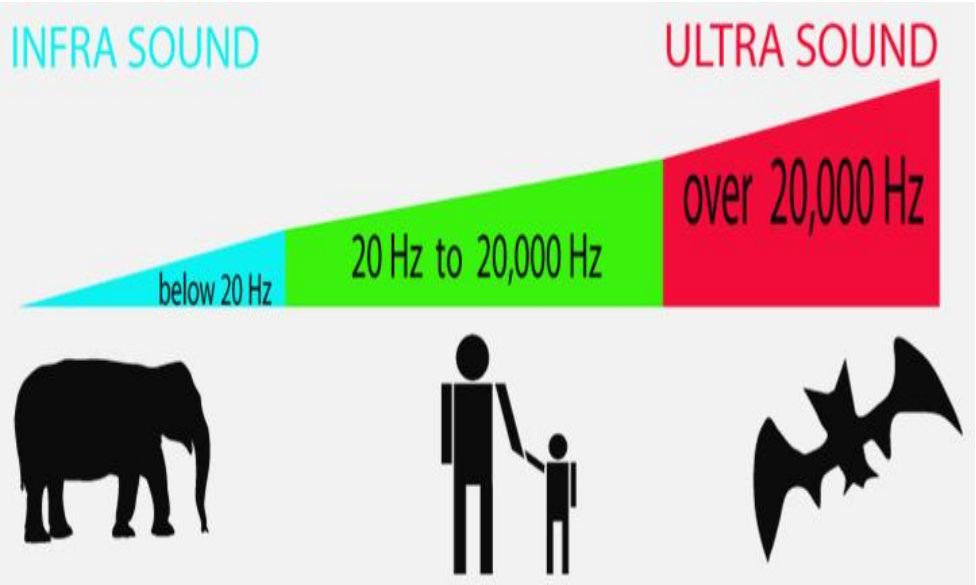

Advantages :

- Non expensive
- Non Ionizing
- Non invasive
- Real time imaging
- Diagnostic & interventional

US image of Gall Bladder stone

Indications :

US have **wide range of indications**, for most of body organs & systems such as:

- **Abdominal US** : trauma, acute abdomen , tumors scan ……etc
- **Chest US** : detection of small amount of effusion *(more sensitive than X ray)*
- **Trans-cranial US:** in infants before Ant. Fontanel closure.
- Neck, Breast, Obstetric , Scrotal , Trans-vaginal, Trans-rectal, soft tissue , ……..etc
- **Color Doppler** : for examination of Vascular system

Different Types of Ultrasonography Probes (Transducers)

✍ Limitations of US use :

- **Gases**: Gases are scattering US waves → masking organs below it (eg. Emphysema, Intestinal gases)
- **Bandages :** as casts & postoperative bandages
- **Non co-operation**: almost all radiological examinations need calm, co-operative patient.

Computed Tomography CT

Basics of Work :

- **Energy used**: X ray , an ionizing radiation (higher Dose than X ray scans).
- **X ray** is librated from **rotating X ray tube**, around patient penetrating body & received on X ray sensors, → send to CT control → images are formed as a cut sections (mainly Axial scans).

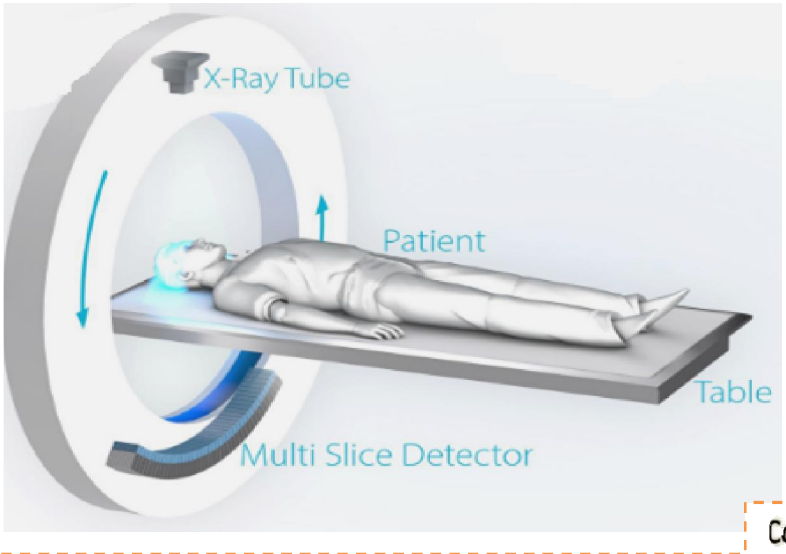

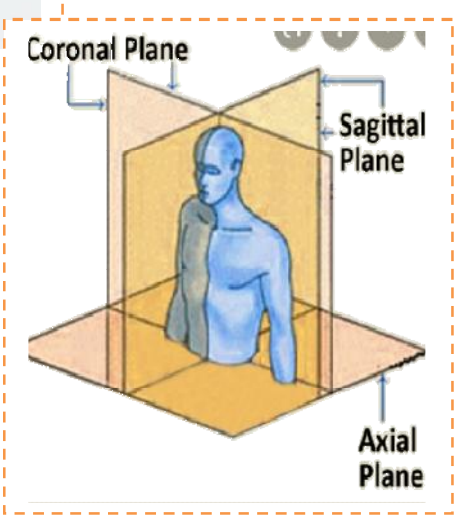

✍ Reporting terms:

- ✍ **Bright object,** *which absorb X ray* = **Hyperdense** (eg. Bone , metals, stones …..etc)
- ✍ **Dark object,** *which permeate X ray* = **Hypodense** (eg. , Fat , air……etc)

CT Densities of different structures is measurable , by the unit of **Hounsfield (Hu)** as described below :

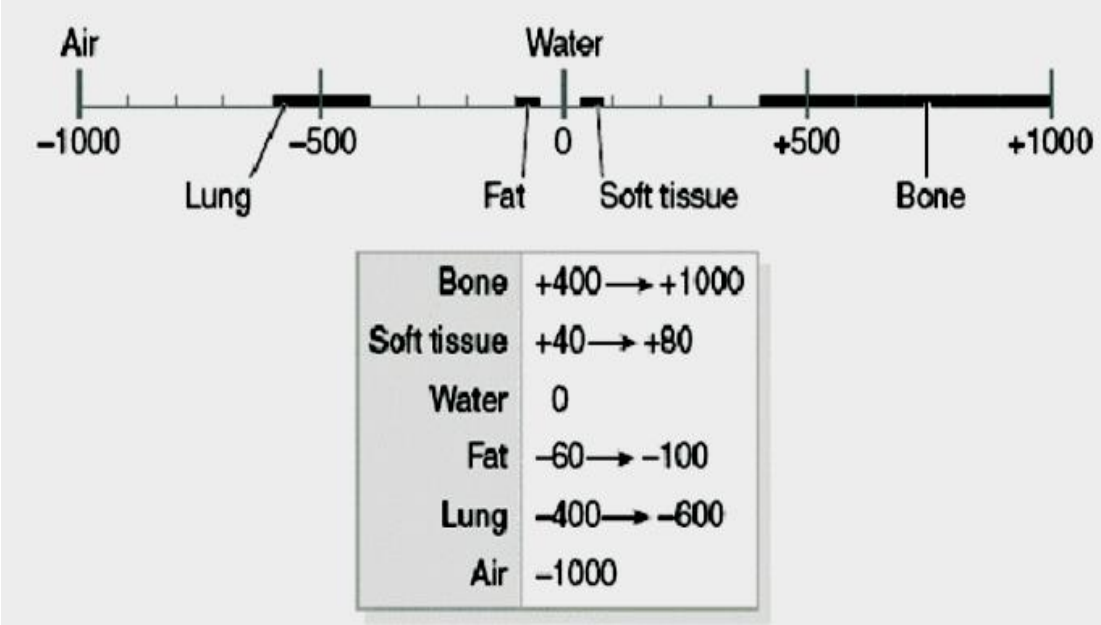

✍ Indications :

CT is usually indicated after **X ray** & **Ultrasonography** are not solving the problem or reaching definite diagnosis , many indications of CT such as :

- ☞ **Neuro Imaging :** Stroke, Trauma, Brain Tumors , vascular lesions, congenital malformations…..etc
- ☞ **Chest imaging** : Infections, trauma, Tumors ……etc
- ☞ **MSK imaging**
- ☞ **Renal Imaging :** stones , tumors, congenital diseases ……etc
- ☞ **Trunk Imaging**
- ☞ **Vascular Imaging:** CT angiography for vascular diseases.

Don't Forget

IV Contrast is mandatory for any CT brain for diagnosis or follow up of any BRAIN TUMORS.

Contraindications:

- **Pregnancy** : especially early

  (Patient or relative)

- **Contrast Hypersensitivity**

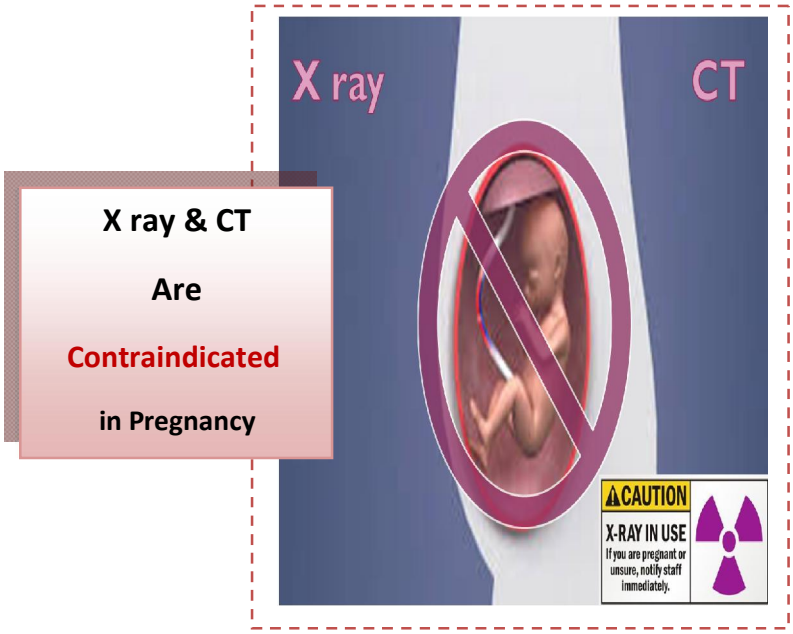

X ray & CT

Are

Contraindicated

in Pregnancy

CT Machine

Magnetic Resonance Imaging MRI

Basics of Work :

- **Energy used**: Magnetic Field + Radio Frequency
- Depending on **Magnetic Resonance Phenomena**
- **Reporting term** = Signal Intensity
  - ✓ Bright object = **Hyper intense**
  - ✓ Dark object = **Hypo intense**

Summary of MRI Work Physics

للإطلاع فقط

- Protons has **+Ve** charge.
- Hydrogen nucleus contains 1 **Proton**.
- Protons are rotating → Act as small magnet → Magnetic field around.
- **(Body net magnetization = near 0)** - Although all these H protons, as small magnets within the body , But due to direction of rotation is variable & against each others.
- **Magnet** → Uniting the direction of rotation of protons.
- **Coil** → **R**adio**f**requency **"RF"** → Change angle of protons by acquiring energy
- **"RF"** stop → Protons miss energy → apparatus receive energy & forming Image from

Types of MRI	
• **According to shape:**	• **According to Magnet Type :**
▪ Open ▪ Closed ▪ Dynamic ▪ Extremity	▪ Permanent ▪ Electeric ▪ Super magnet

⇨ Why to use Open MRI :

- For Cases of **Claustrophobia** & **Morbid Obesity.**

MRI Sequences & appearance of different structures

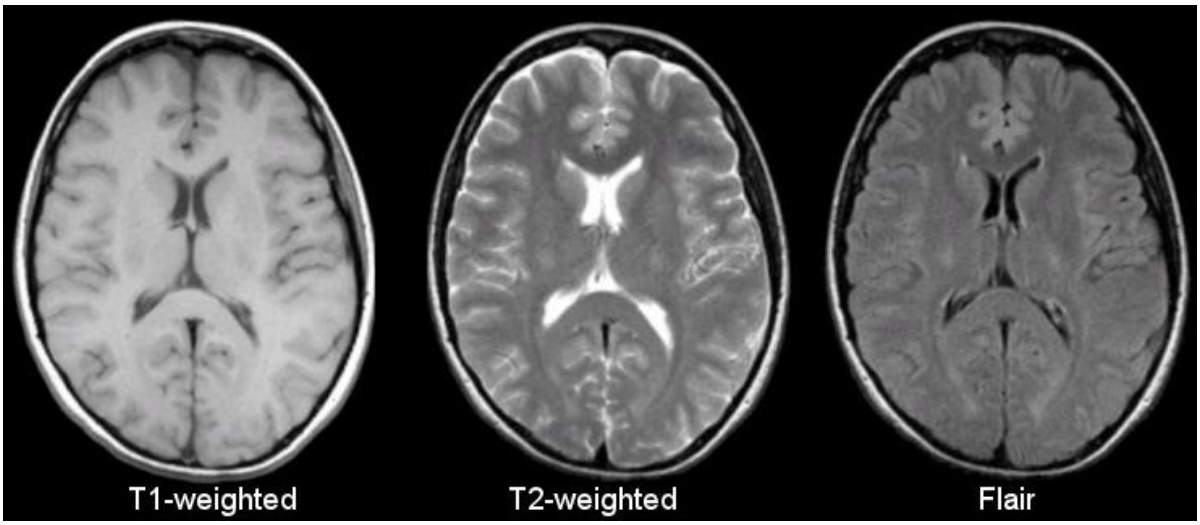

Normal MRI in Different Sequences

Contraindications: Any Ferromagnetic material

- ☒ Pacemaker (Fatal)
- ☒ Any Iron FB
- ☒ Contrast Hypersensitivity
- ☒ Fire arm / Vascular metallic clips

Don't Forget

MRI is large powerful Magnet

Warning of Use seen at every MRI Unit

Indications: (Many organs, Many Systems)

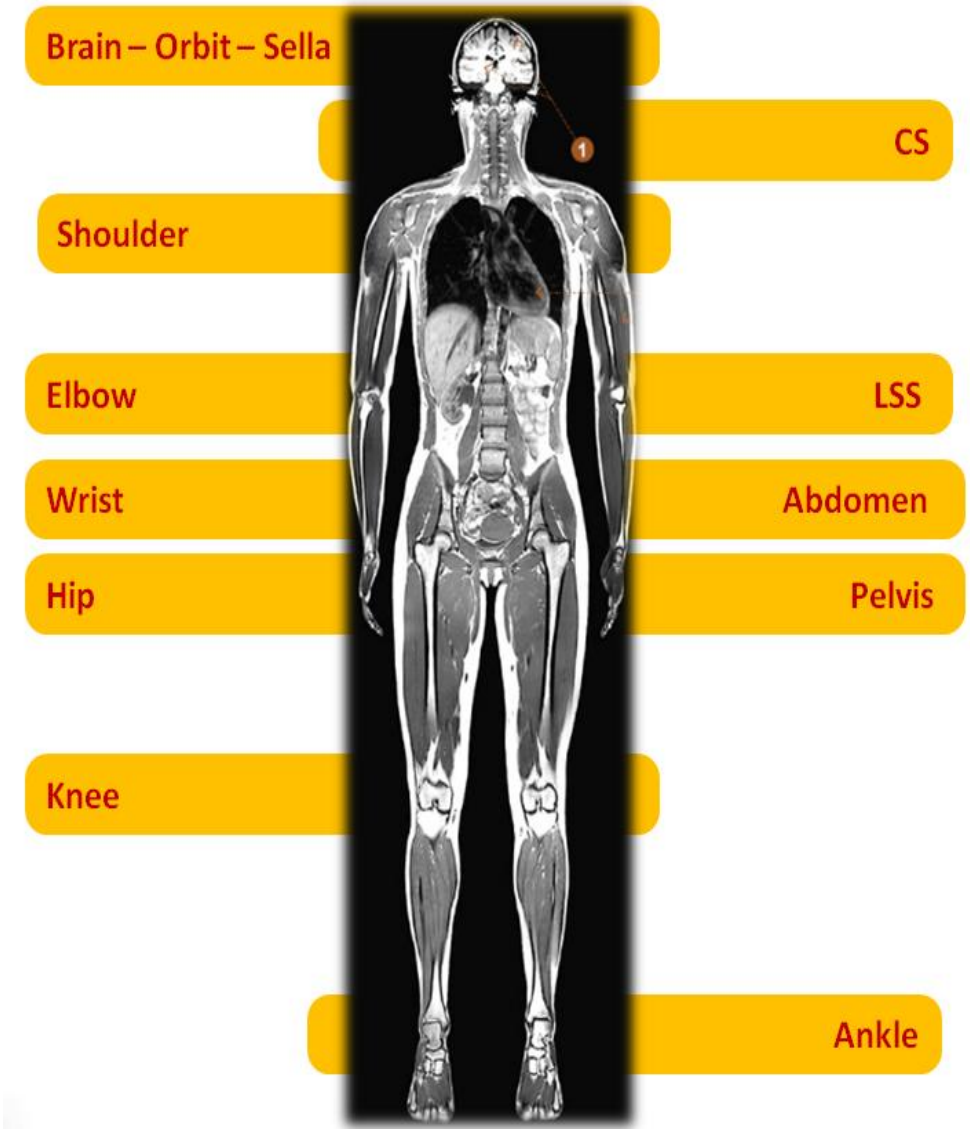

Hints about Indications:

✓ **DW (Diffusion Weighted MRI)**

The fastest Method to detect Acute cerebral infarction.

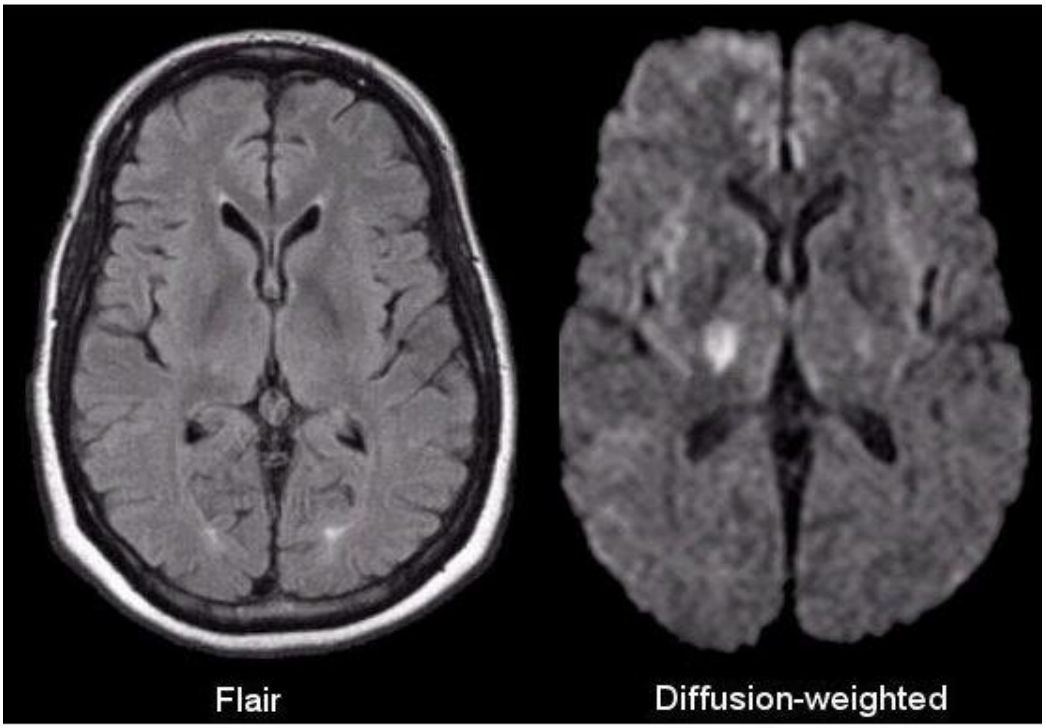

Note the Acute Infarction Only Seen on DWI

Advantages of MRI

- ✓ **Non Ionizing Radiation**
- ✓ **Non iodinated Contrast (Gadolinium)**
- ✓ **Best soft tissue differentiation** by **Multi Sequences**
- ✓ **Multi planner** : scan at any direction

MRI *Is*

Multi planner

Multi Sequences

Disadvantages of MRI

- × **Expensive / Limited availability**
- × **Limited use in Lung / cortical bone Imaging**
- × **Ferromagnetic Contraindications**
- × **Long scanning time**

Contrast

Contrast: Injected or ingested material that improve radiological detection of certain structure or organ.

Type of contrast materials

[A] Barium sulphate: for evaluation of the gastrointestinal tract

[B] Water soluble contrast materials

- **Oral use :** Gastrographin
- **IV injection :** Urographin ,Telebrix

[C] Oily contrast media : Lipiodol ultra- fluida

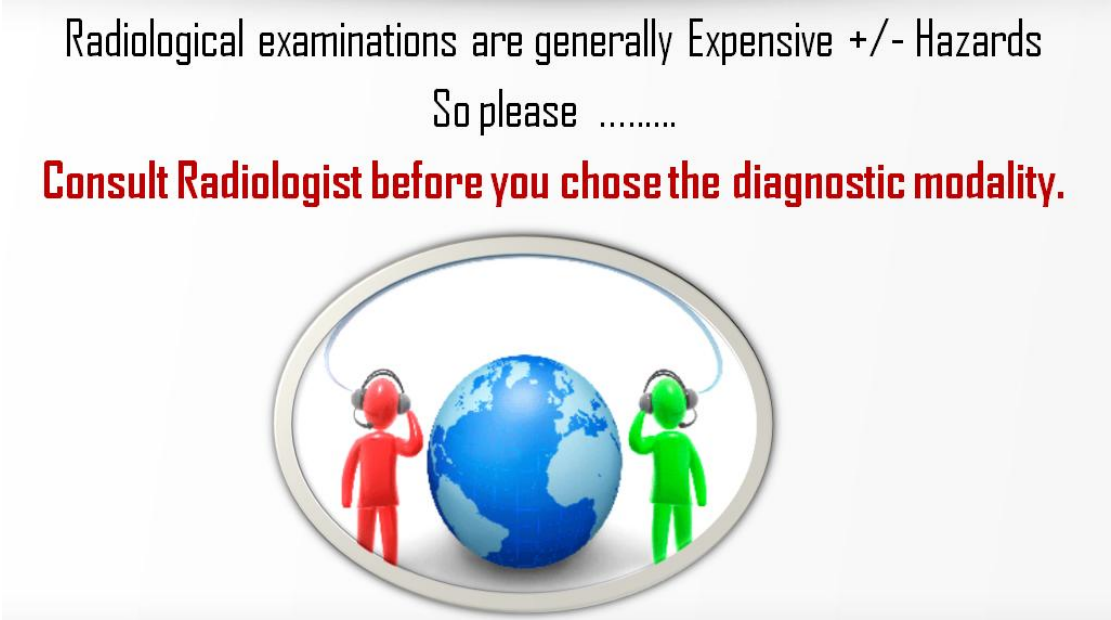

Basics of CNS Imaging

Imaging Modalities of CNS

- ✓ **CT :** Commonest Modality , & initial for assessment.
- ✓ **MRI :** usually used when CT is non-conclusive
- ✓ **Trans cranial US:** For initial assessment of hydrocephalus in infants.
- ✓ **X ray :** Limited use

…….. & Others

✍ **Don't Forget**

CT is contraindicated in Pregnancy

MRI is contraindicated in pacemaker & Ferromagnetics

Normal CT Brain Anatomy

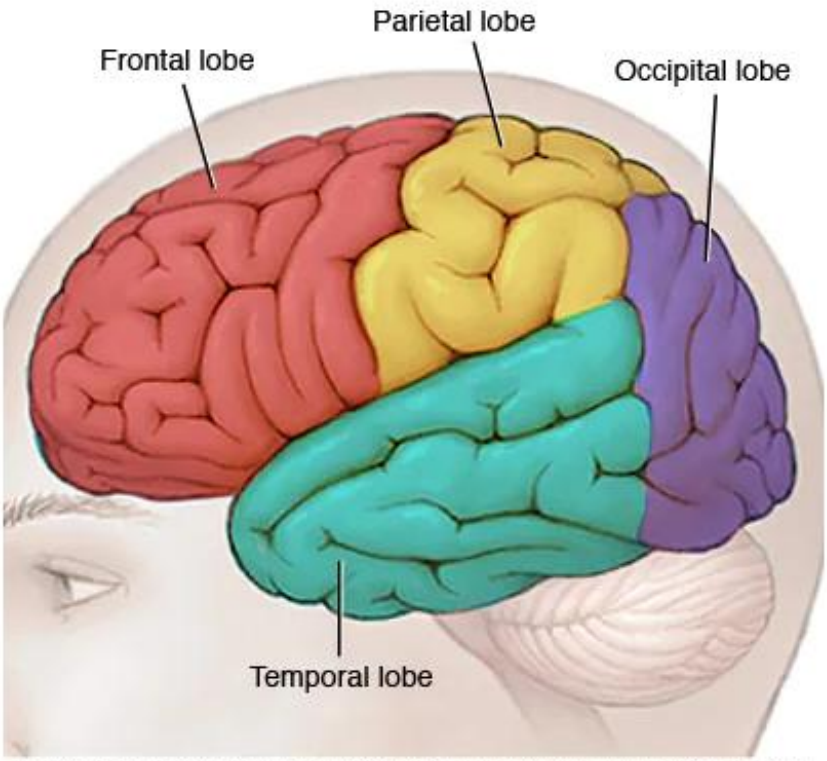

© MAYO FOUNDATION FOR MEDICAL EDUCATION AND RESEARCH. ALL RIGHTS RESERVED.

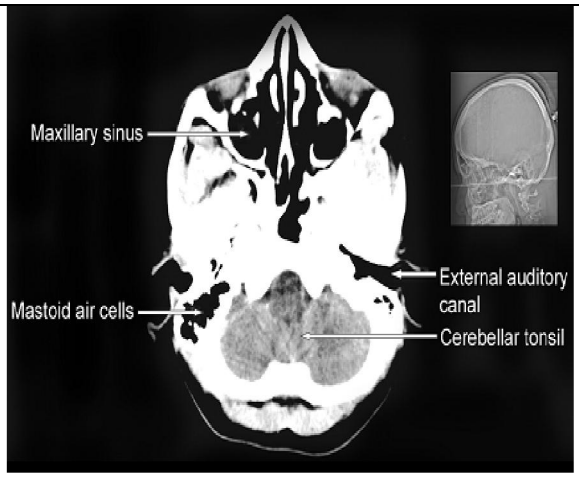
Maxillary sinus
External auditory canal
Mastoid air cells
Cerebellar tonsil

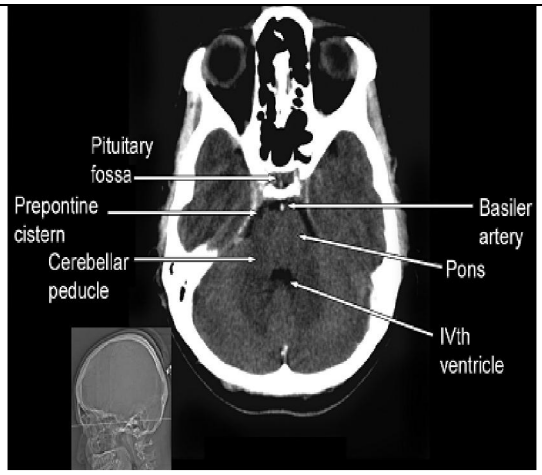
Pituitary fossa
Prepontine cistern
Basiler artery
Cerebellar peducle
Pons
IVth ventricle

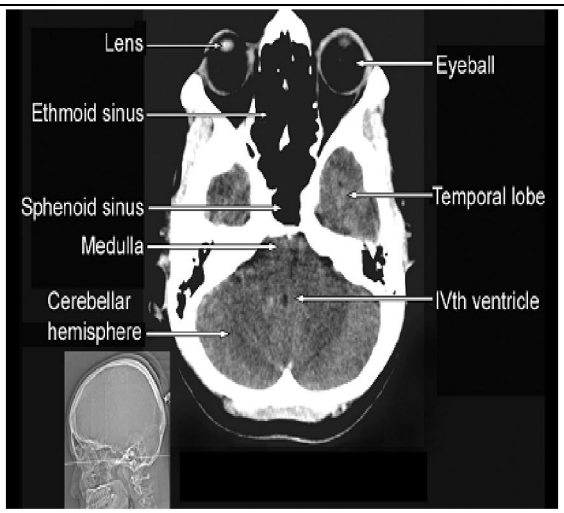
Lens
Eyeball
Ethmoid sinus
Sphenoid sinus
Temporal lobe
Medulla
Cerebellar hemisphere
IVth ventricle

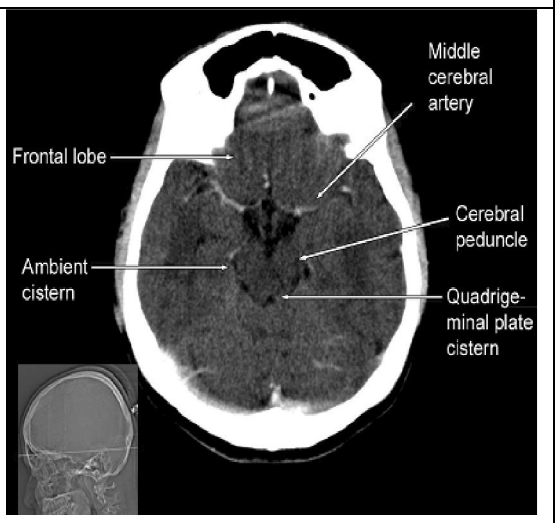
Middle cerebral artery
Frontal lobe
Cerebral peduncle
Ambient cistern
Quadrige-minal plate cistern

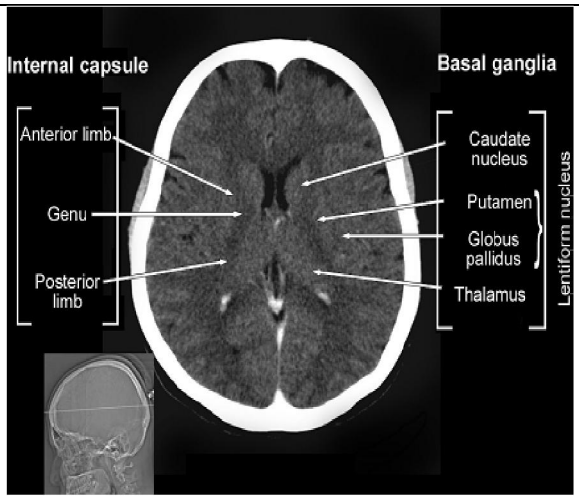
Internal capsule
Basal ganglia
Anterior limb
Genu
Posterior limb
Caudate nucleus
Putamen
Globus pallidus
Thalamus
Lentiform nucleus

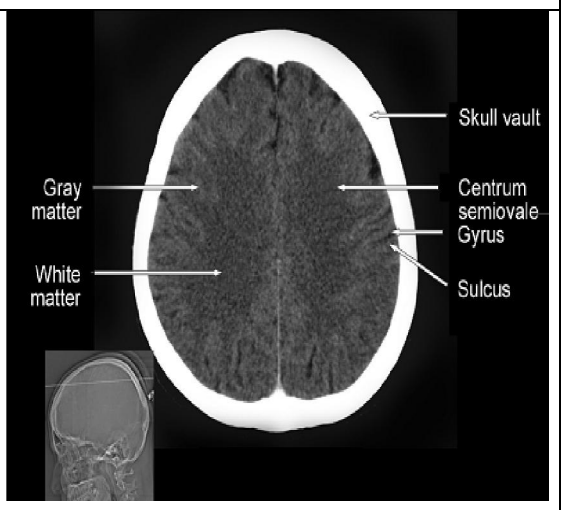
Skull vault
Gray matter
Centrum semiovale
Gyrus
White matter
Sulcus

Practical Question:

What is CT window?

Is imaging setting of the same cut section make cretin organ seen better

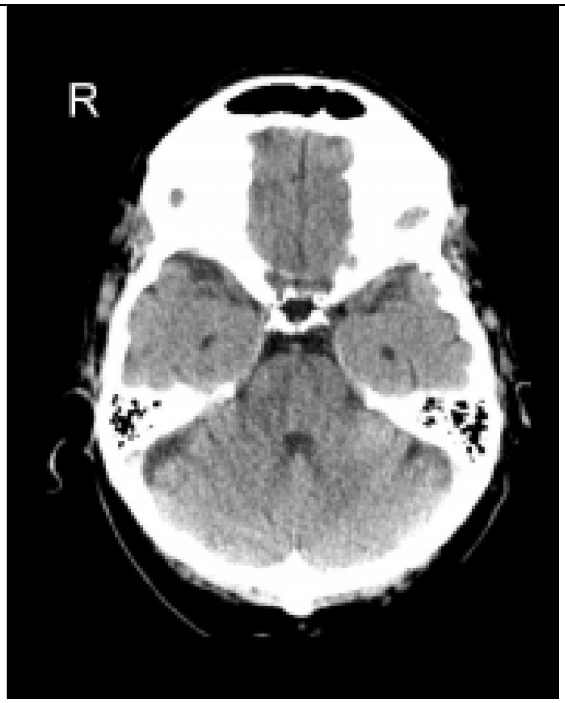	
Brain Soft Tissue window	**Brain bone window**

CVS (Cerebro-Vascular Stroke)

® **CVS :** interruption of the blood supply to any part of the brain

® **Types :** It may be

- **Ischemic** (Infarction)
- **Hemorrhagic** (intra cranial Hemorrhage)

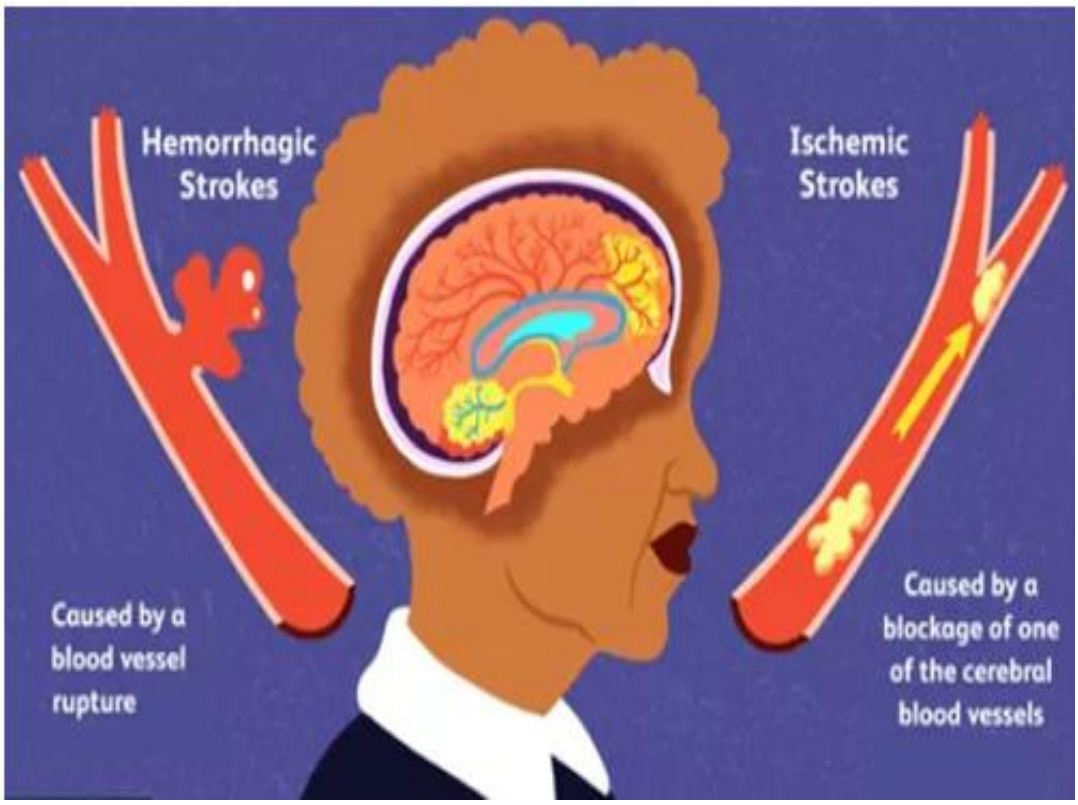

Don't Forget

® **Clinical Picture is the first Key for Radiological Diagnosis**

® Clinical Picture :

- **Neurological deficit :** according to site of lesion
  + Other Findings

® Imaging Modalities:

- **CT :** Main method

Infarction	Hypo dense cortical lesion *(the more duration , the more hypo dense)* **So Chronic infarction appears as CSF density**
Hemorrhage	Hyper dense area of fresh blood density. **(60 : 90 Hu)**

Cerebral Infarction may not appear in CT before 24 h

DW MRI can detect cerebral infarction after 2 min

- **MRI:** Less commonly used than CT

Infarction	**Hypo Signal** cortical lesion in **T1** & **Hyper signal** in **T2** & **FLIR** ***DW :*** *restricted diffusion*
Hemorrhage	Variable appearance according to duration

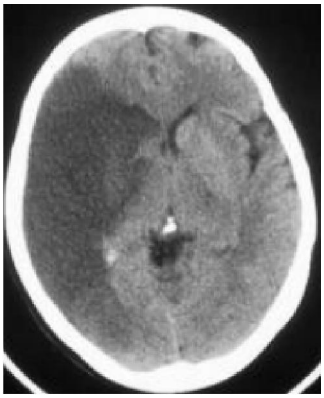

ACUTE INFARCTION

CHRONIC INFARCTION

I C Hemorrhage

➲ **Practical Question: What is mass effect?**

Mass effect = the effect of **S**pace **O**ccupying **L**esion **(SOL)**

As Tumor, Haemorhage , Abscess ….. etc

SOL → Mass effect (According to its size & Site)

Mass effect =

- ➲ Effacement of cortical Sulci
- ➲ Compression of ventricle
- ➲ Shift of medline

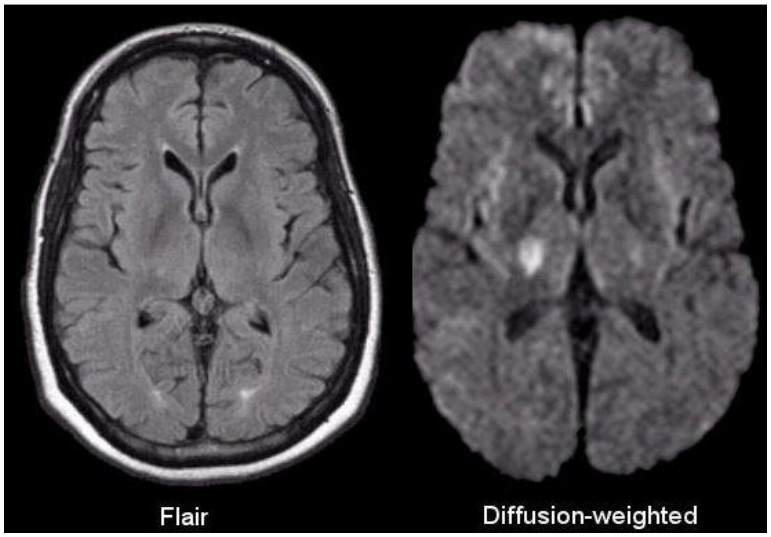

Rt Thalamic Infarction appears as area of restricted diffusion in DW MRI

➲ **Practical Question:**

Why acute cerebral infarction is causing Mass effect?

➲ **By related cerebral edema**

Large Lt cerebral Infarction

Notice its mass effect due to associated cerebral edema.

CEREBRAL EDEMA

2 Main types:

- Cytotoxic & - Vasogenic

	Vasogenic	Cytotoxic
Pathology	Extracellular accumulation of fluid	Cell swelling caused by intracellular accumulation of fluid
Etiology	SOL (Tumors, Abscess….etc)	Cerebral infarction
CT Picture	Fingers like area around lesion	Hypodense patch around lesion

Head Trauma

Head trauma can lead to:

- ✓ **Skull Fractures :** *(Seen in bone window)*
  - **Fissure,**
  - **Depressed ,**
  - **comminuted &**
  - **skull base fractures**
- ✓ **Hematomas :**
  - **Extradeural ,**
  - **Subdural**
- ✓ **Cerebral Contusions**

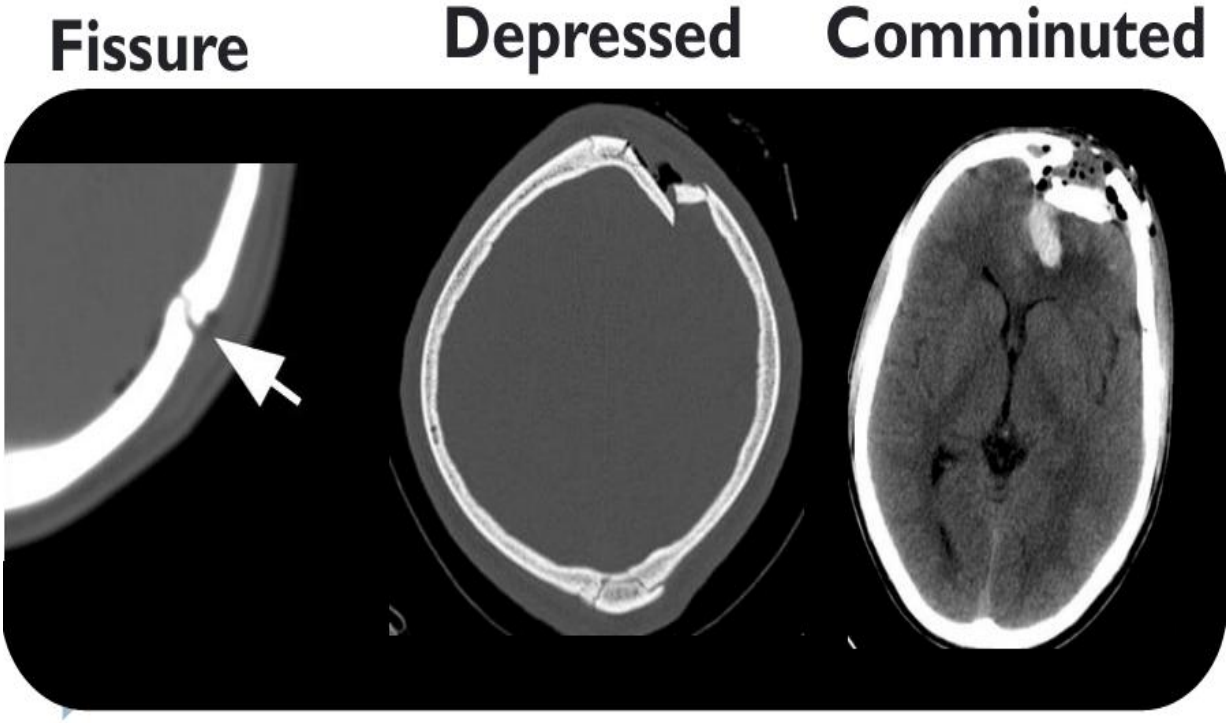

Types of Skull Fractures

Types of Intra cranial Hemorrhages

Extra dural	Sub dural	Sub arachnoid
	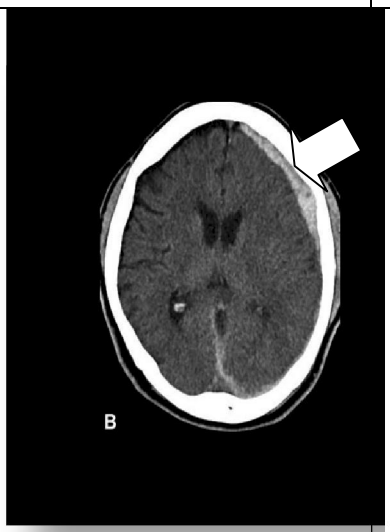	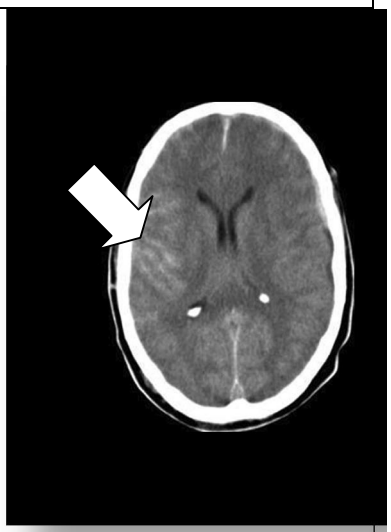

Intra cerebral	Intra ventricular
	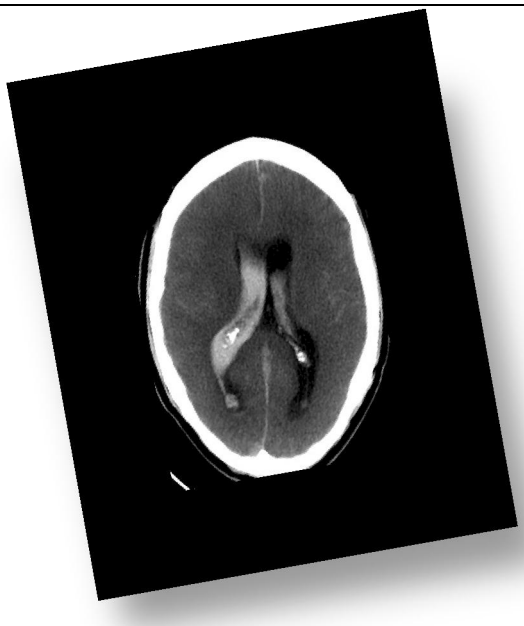

Hematoma Type	CT Appearance
Extra dural	Lens shape or Biconvex shape hematoma
Sub dural	Crescent Shape (Inner convex border)
Sub Arachnoid	Fresh blood density smearing sulci
Intra ventricular	Fresh blood density inside ventricles

CECT

Contrast Enhancing CT Brain

✍ Contrast:

IV , Iodinated material eg. *Urografin, Omnepaque or Ultravist* .

✍ Indications :

- ✓ Brain Tumors: **MANDATORY** for suspicion, diagnosis or Follow up.
- ✓ Brain Abscess & infections
- ✓ Vascular Imaging

Patterns of Enhancement

Basics of Chest Imaging

Chest Imaging Modalities

- ✓ **X ray (CXR) :** Initial & basic
- ✓ **CT :** Commonest Modality
- ✓ **MRI :** Limited use (only for assessment of chest wall tumors invasion)
- ✓ **Chest US:** mainly For Detection of Small amount of effusion & **Aspiration under US guide**.

…….. & Others

Again …… Don't Forget

CT is contraindicated in Pregnancy

MRI is contraindicated in pacemaker & Ferromagnetics

CXR (Chest X Ray)

® **Basic radiological modality** for chest assessment

® Indicated For initial assessment of most chest diseases

® Understanding of normal CXR anatomy & pathological descriptive terms is mandatory for good assessment of CXR.

® **P**ostro – **A**nterior view (**PA**) is the basic projection (*See the Figure*)

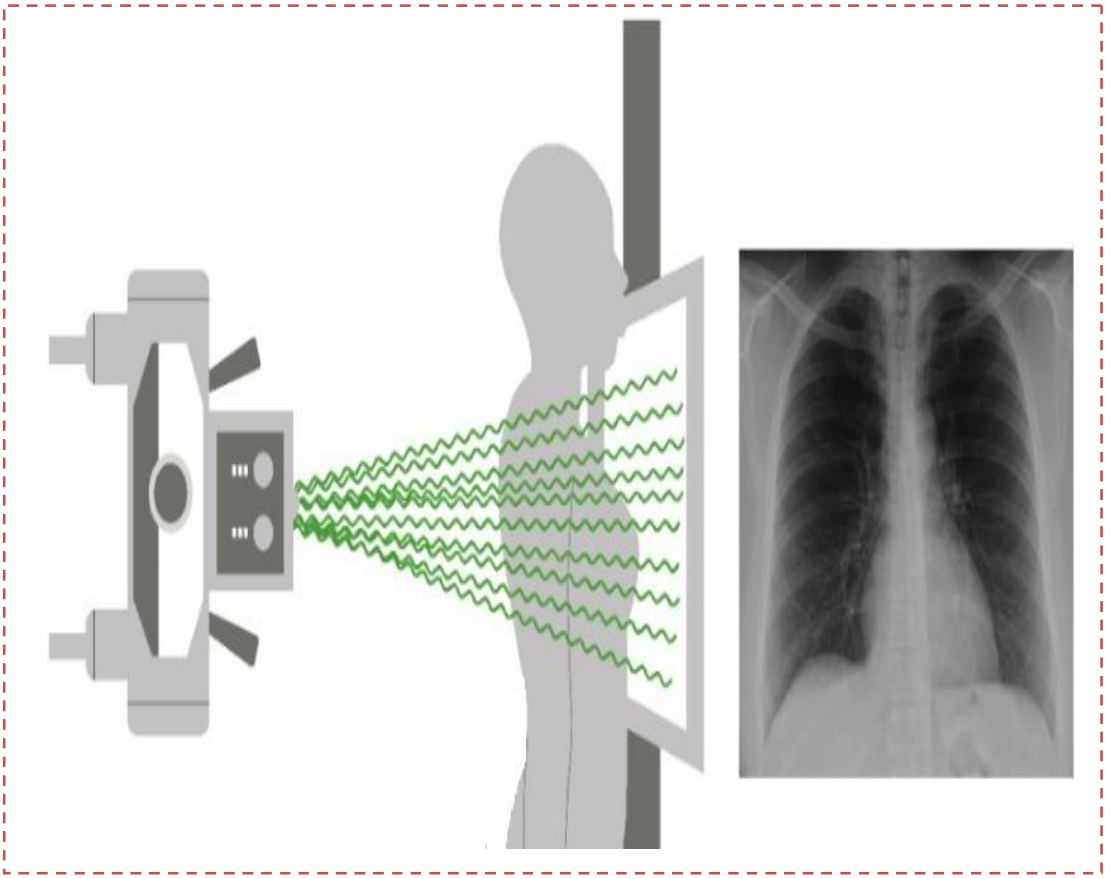

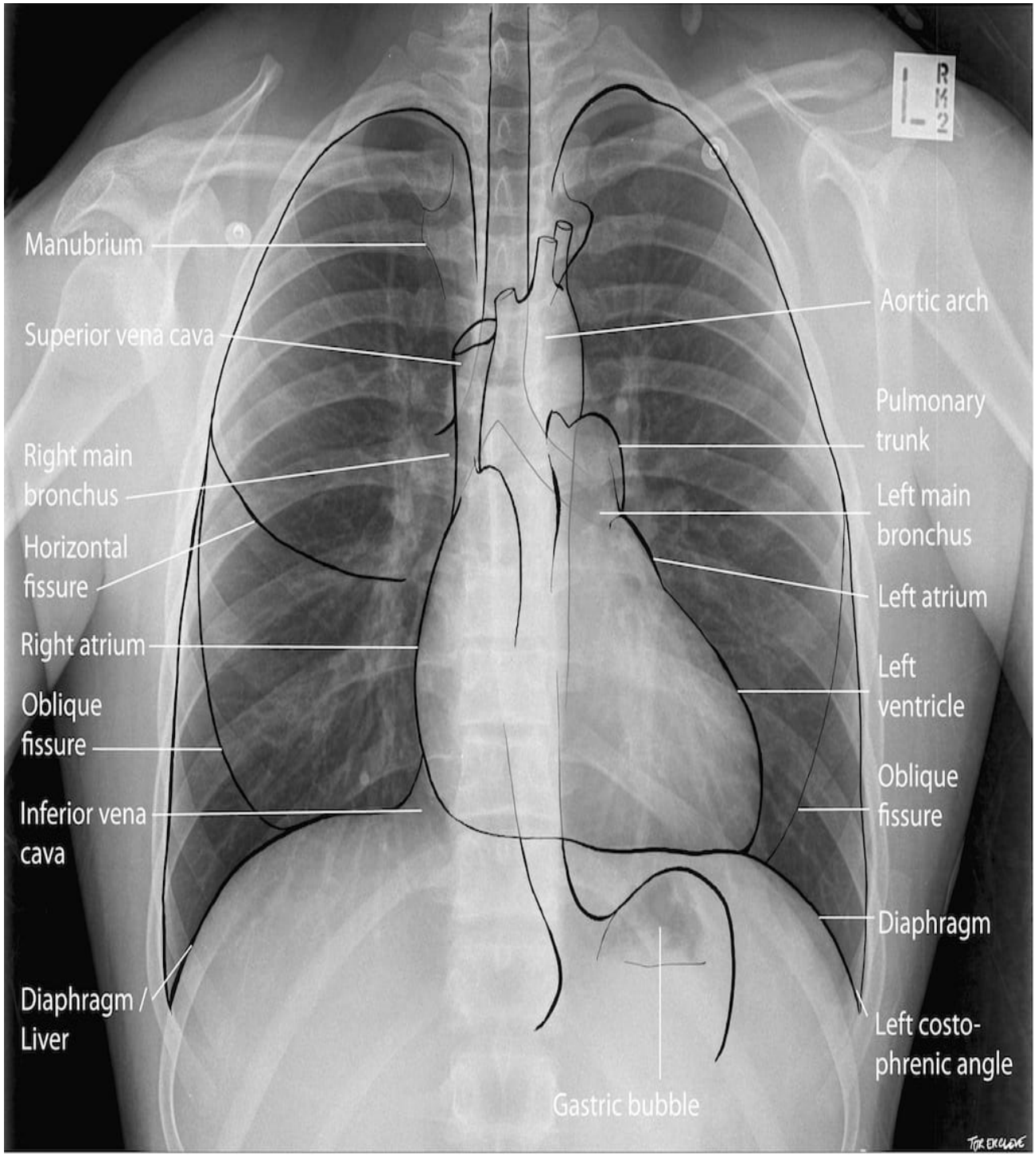

Normal CXR Anatomy

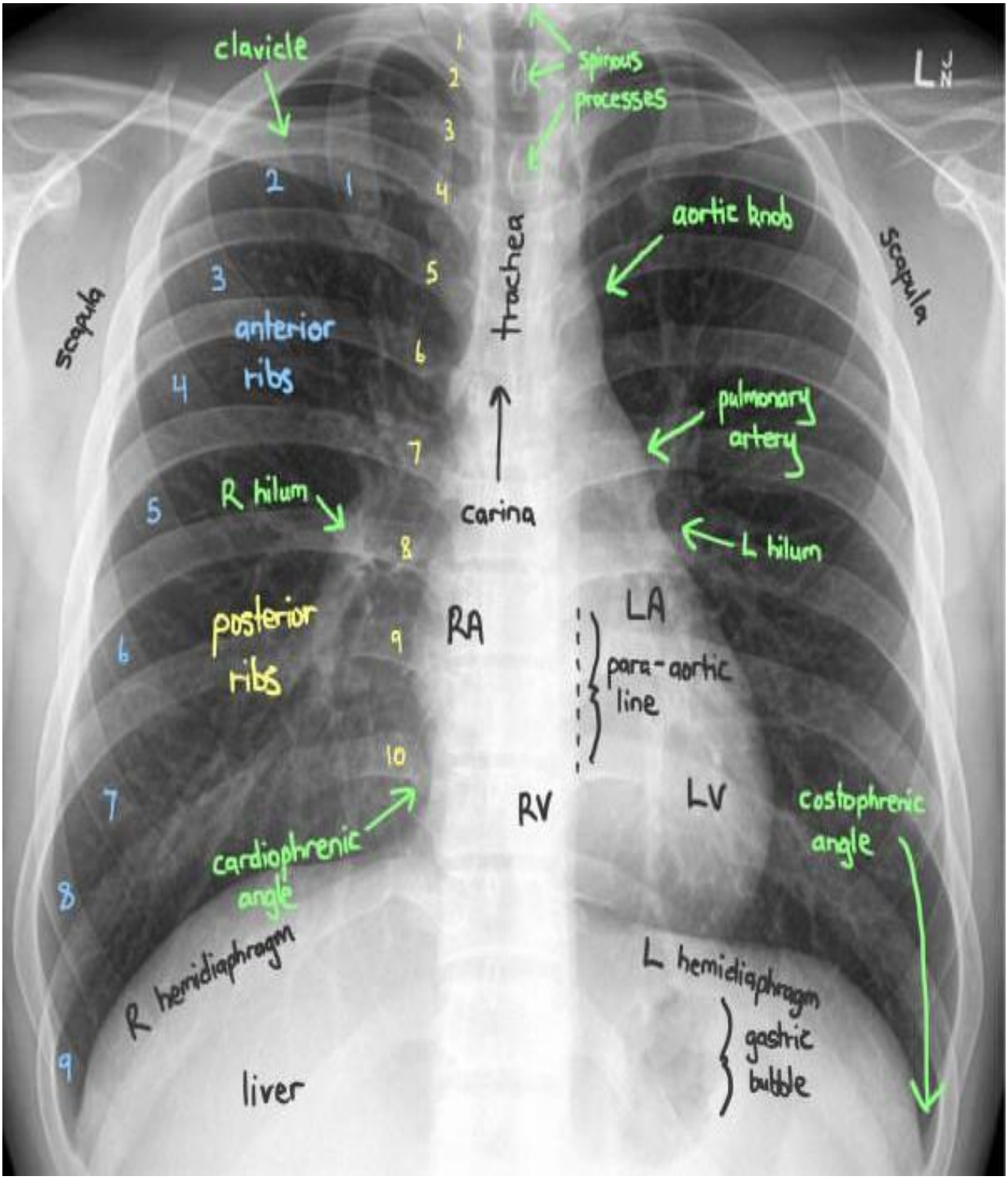

Normal CXR Anatomy

Practical Question :

How to count Ribs?

Begin from posterior to anterior from 1st rib & downward

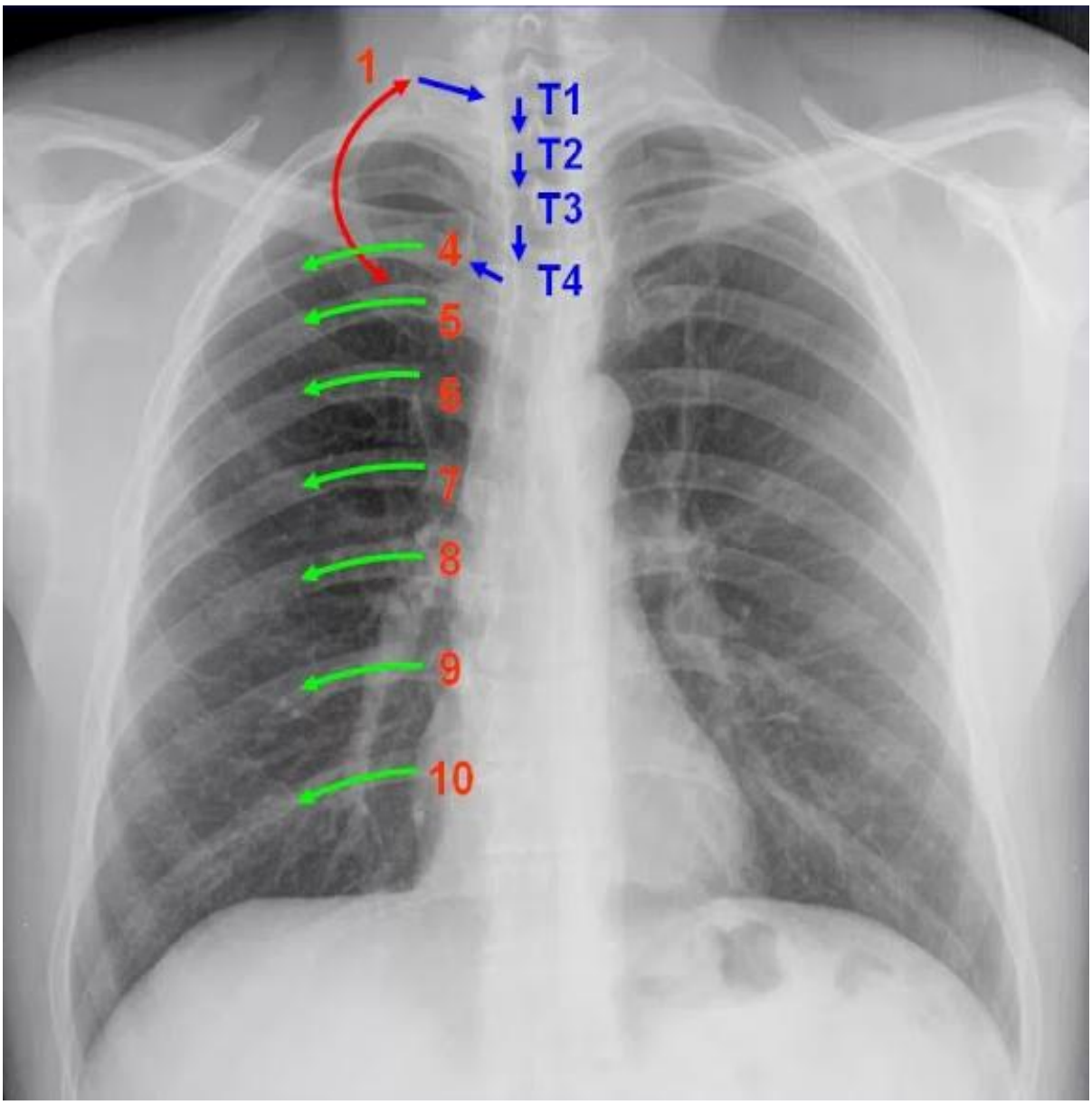

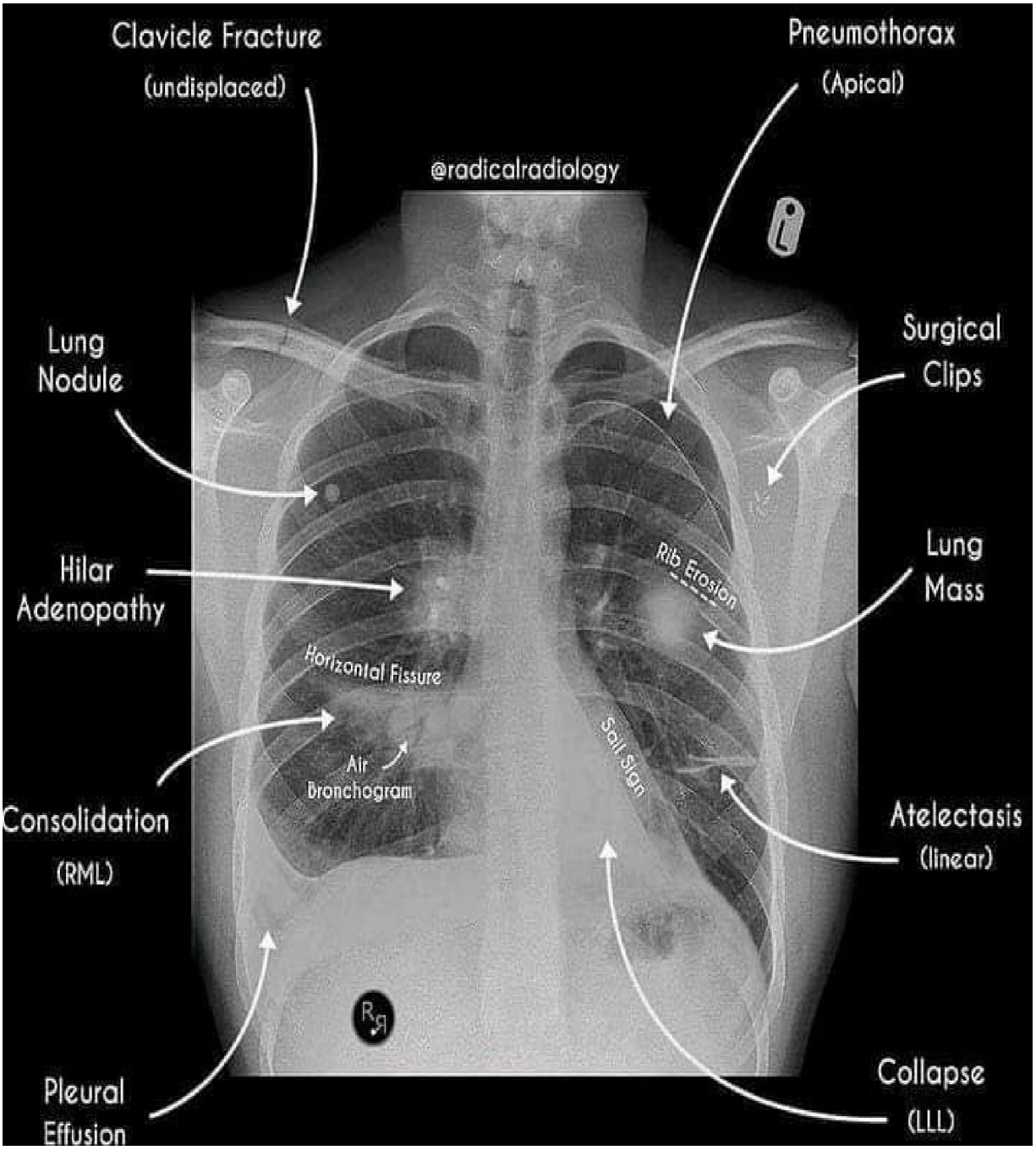

- **Main lesions of CXR**

NB CT examination of the chest should be the next step if you can not accurately diagnose any pulmonary lesion

® **Don't Forget :**

Clinical History & finding is the key for radiological Diagnosis

In CXR:

Item to be evaluated:

- **Lung parenchyma**
- **Costophernic sinuses**
- **Cardiac** size and shape
- **Chest wall** including ribs, scapulae, clavicles and spine
- **Extra thoracic** soft tissues specially
  - Shoulder joints
  - Lower neck
  - Breast shadows [females]

Chest Pathology

FOCAL LUNG LESIONS

X rays

4 types of focal lesions

- Nodules
- Masses
- Patches
- Cavities

✓ **Nodule :** well defined focal lung Lesion , **less** than 3 cm

✓ **Mass :** well defined focal lung Lesion , **More** than 3 cm

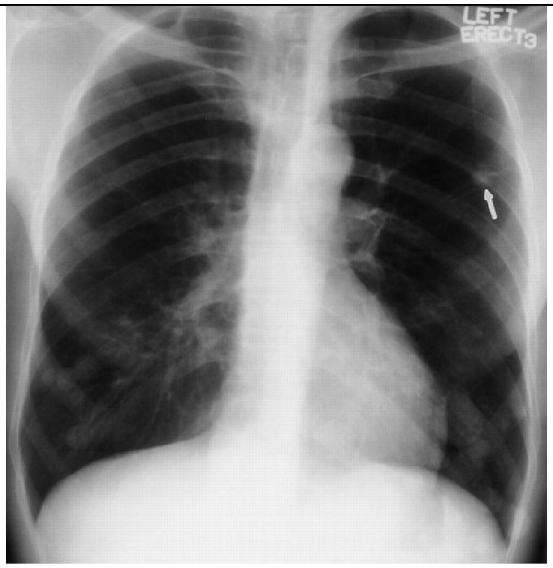

Lt upper zone, peripheral lung nodule

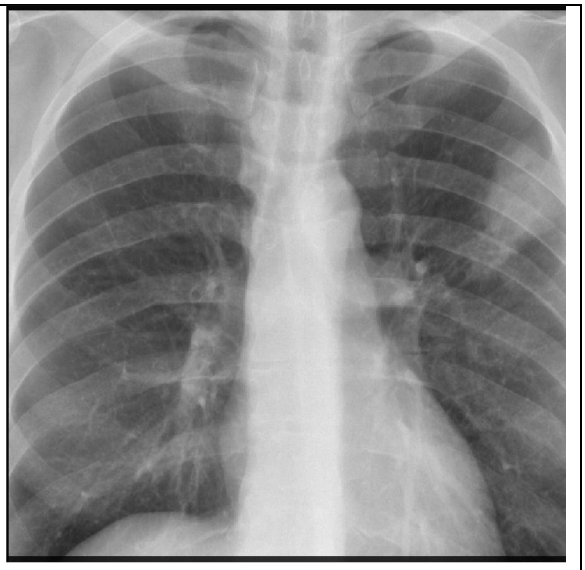

Lt upper zone, lung mass

Q. What are CXR lung Zones?

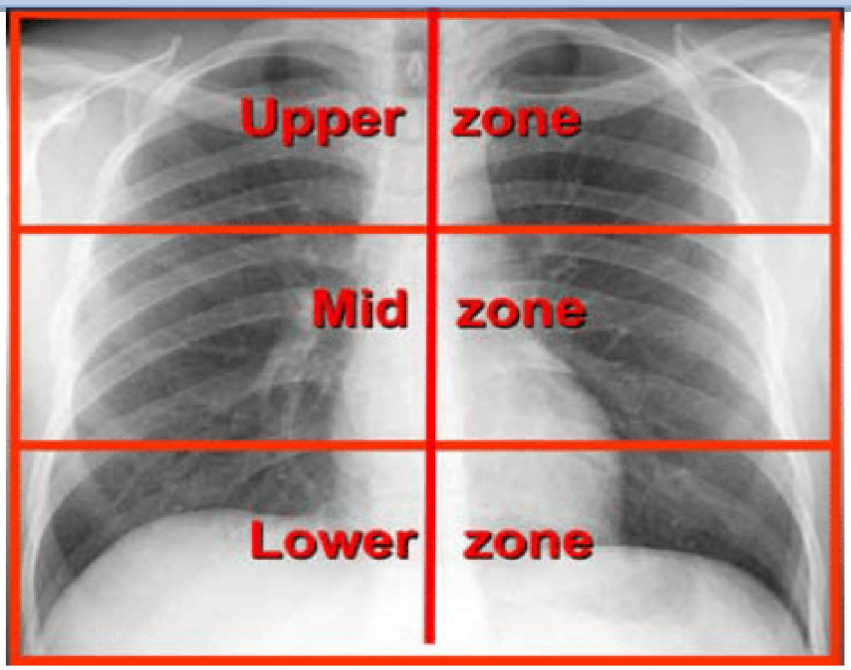

PATCHY OPACITY [Ill- defined lesion showing air bronchogram]

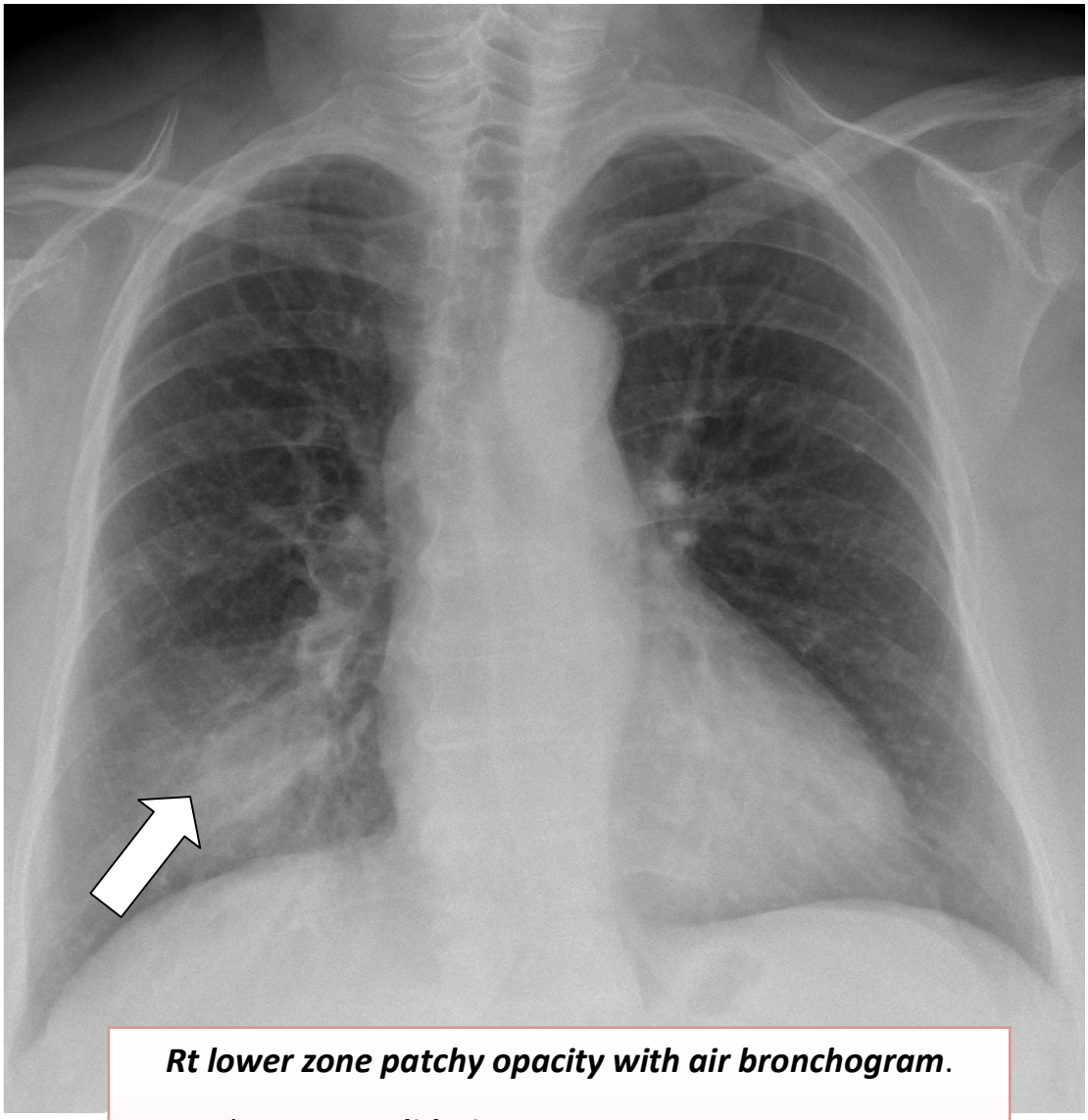

Rt lower zone patchy opacity with air bronchogram.

- Patch + = **Consolidation**
- Usually Pneumonia.
- Patch may be single or multiple
- **Air Bronchogram =** Patent airways between alveoli filled with fluid.

CAVITARY LESION [A well defined lesion that is totally or partially containing air]

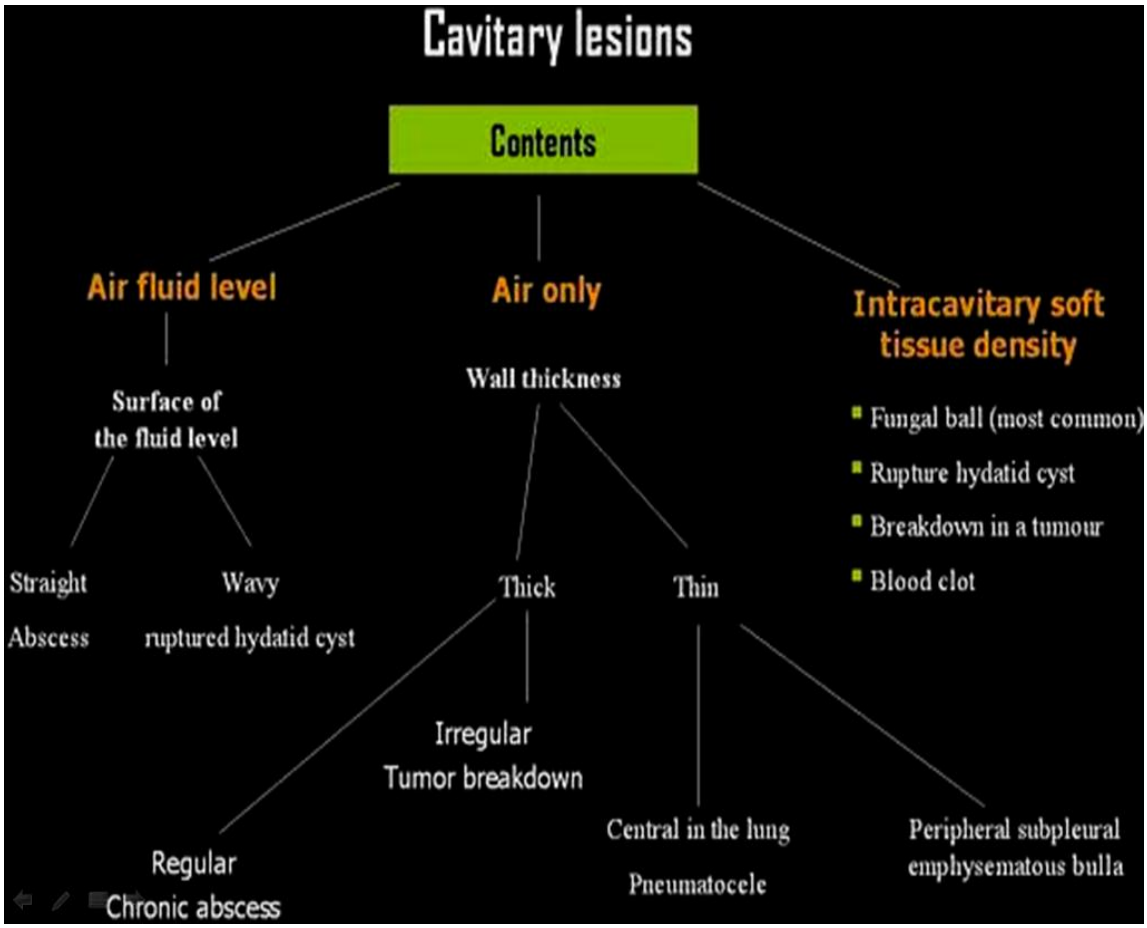

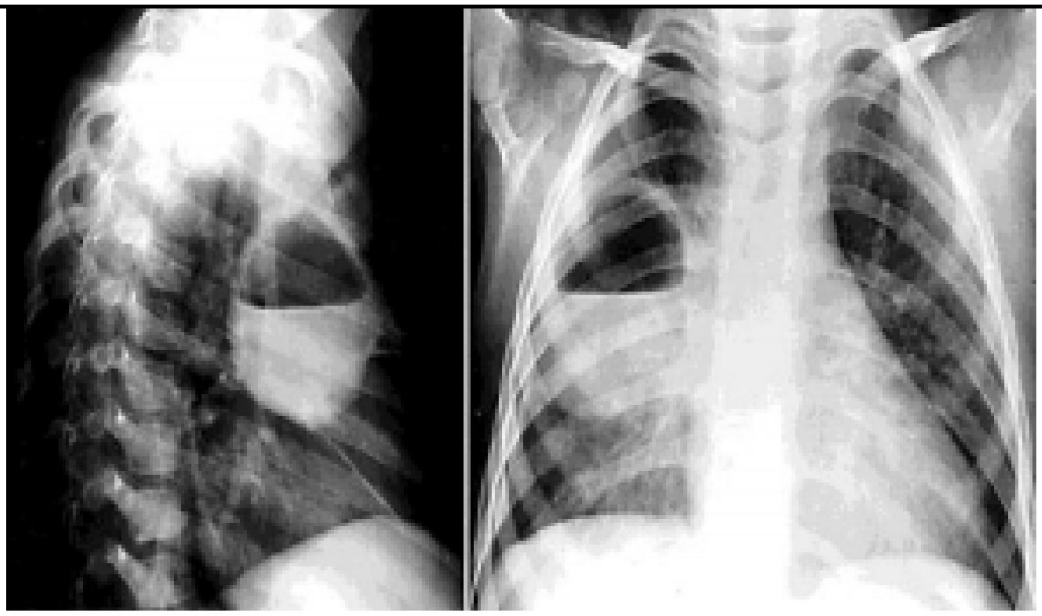

Lung Abscess

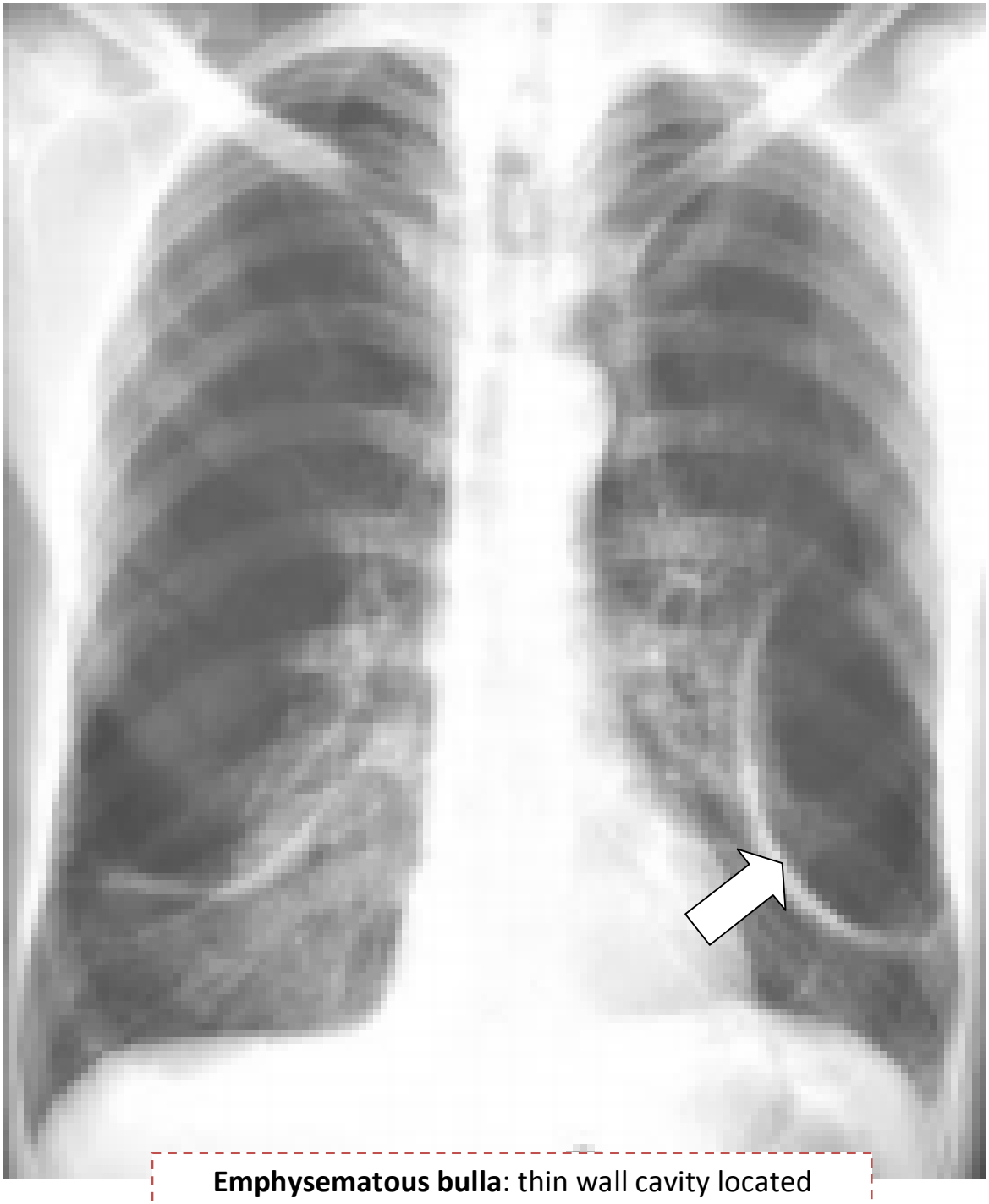

Emphysematous bulla: thin wall cavity located peripherally at lt lower zone near the chest wall

Pleural Pathologies

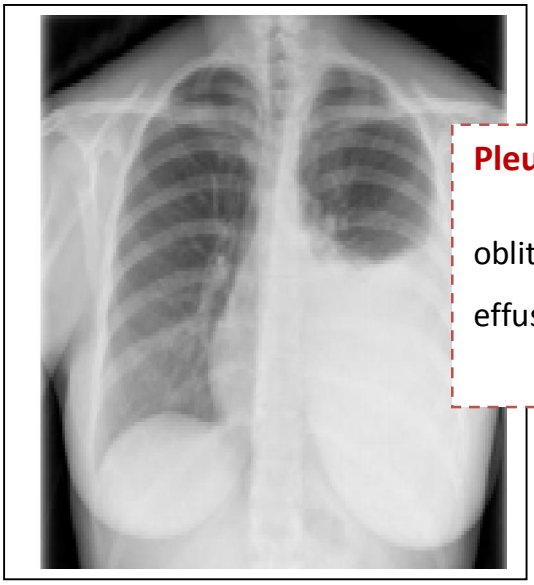

Pleural effusion: *(Fluid in pleural cavity)*

obliterated left costophernic angle by pleural effusion with upper border raising to axilla

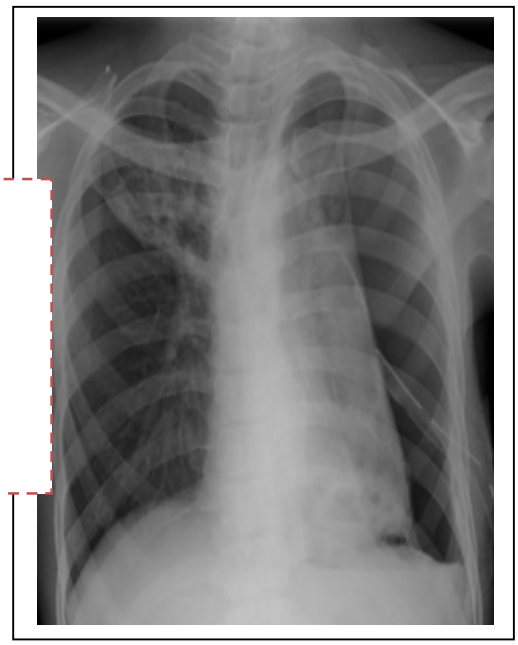

Pneumothorax : *(Air in pleural cavity)*

Left side jet black lucency with no lung marks.

Notice underlying lung collapse → No shift of mediastinum.

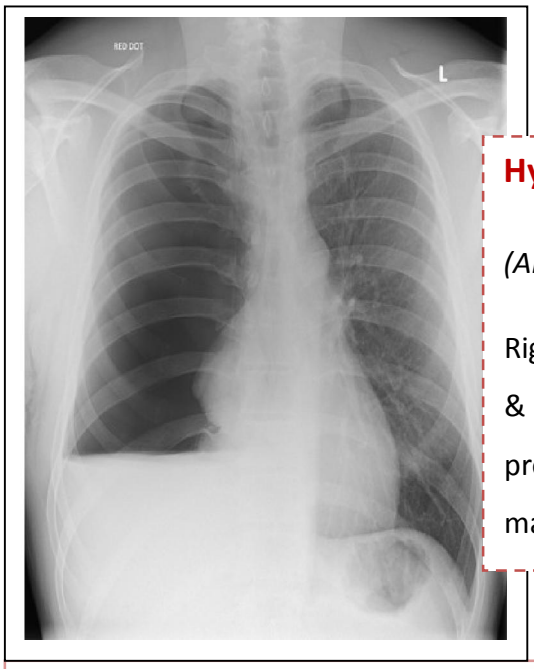

Hydro-pneumothorax :

(Air& fluid in pleural cavity)

Right side pleural effusion obliterating Rt CP angle & lower lung zone, with straight upper border & proximal large jet black air lucency with no lung marks.

Q. what is the difference between upper borders of Pleural effusion & Hydro-pneumothorax …. & Why ?

Chest X ray Illustration Cases

Bilateral Multiple lung masses

Bilateral Multiple lung nodules

Rt lower lung Nodule

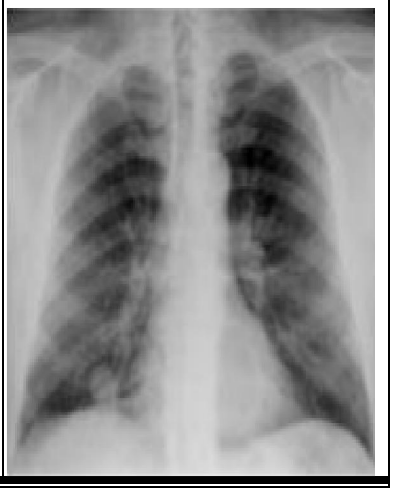

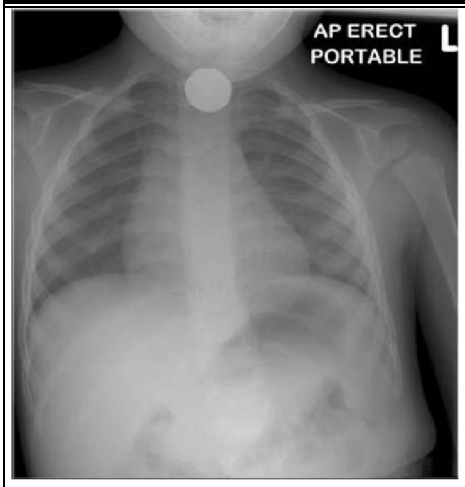

F.B. Inhalation

Rt Minimal Pleural Effusion

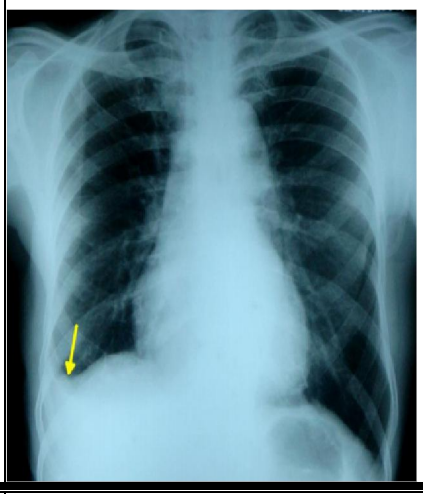

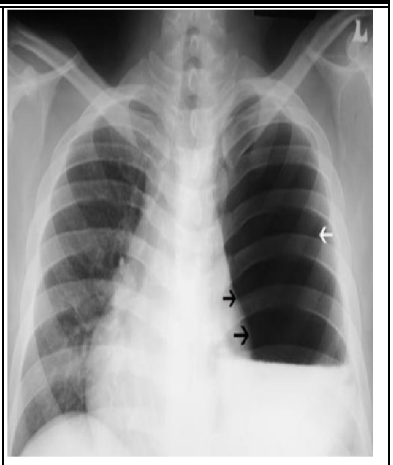

Lt hydro-pneumothorax

Lt Middle zone lung mass

Pneumo-peritoneum
(Air under diaphragm)

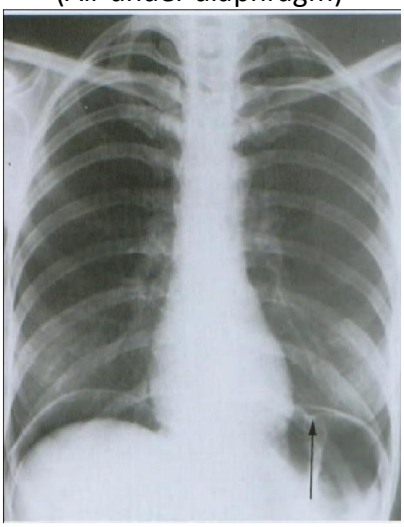

Pericardial Effusion
(Flask Shape Heart)

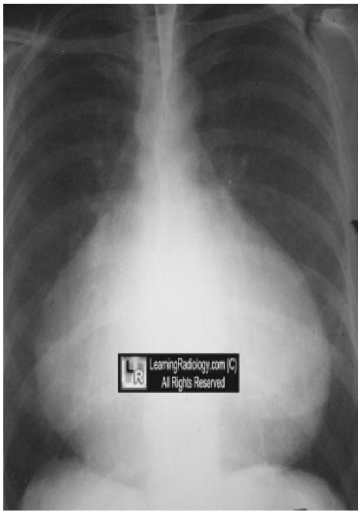

CT Chest

Indications:

- ✓ **Equivocal** plain x-ray findings assessment
- ✓ **Lung neoplasm** staging
- ✓ **Metastatic workup** of extra thoraces malignancies
- ✓ **Diffuse lung diseases Diagnosis** (with HRCT)
- ✓ **Bronchietasis** assessment
- ✓ **Posttraumatic complications** Assessment
- ✓ **Mediastinal** and **chest wall** lesions
- ✓ **Pulmonary embolism** Diagnosis

Don't Forget:

CT chest is done in *2 main windows*

-Lung window &

-Mediastinal Window

Lung Window	**Mediastinal window**

Q. Do You remember what is CT window?

Review previous chapter

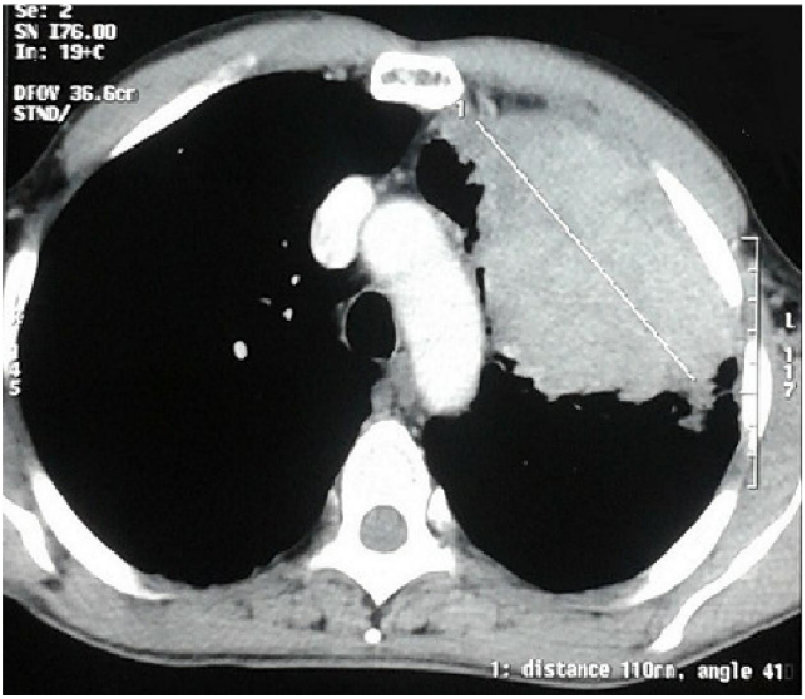

CT Chest – Mediastinal window – Lt lung large mass

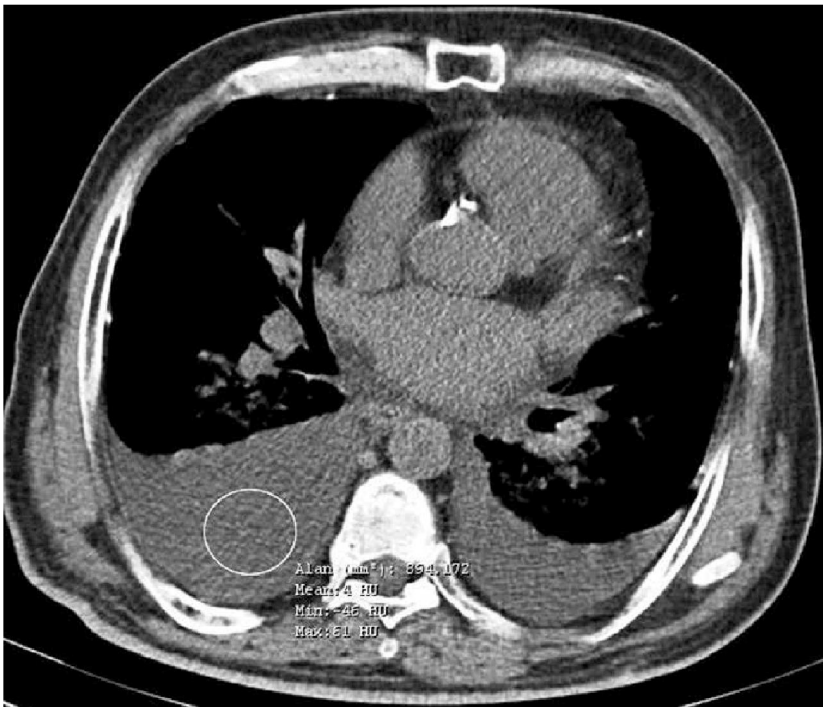

CT Chest – Mediastinal window – Bilateral Pleural effusion

MRI Chest

Indications:

- ✓ Assessment of **vascular abnormalities** *(aorta ،pulmonary arteries, veins, SVC)*
- ✓ Evaluation of **mediastinal masses**
- ✓ Staging of **bronchogenic carcinoma**
- ✓ Diagnosis of **chest wall pathology**

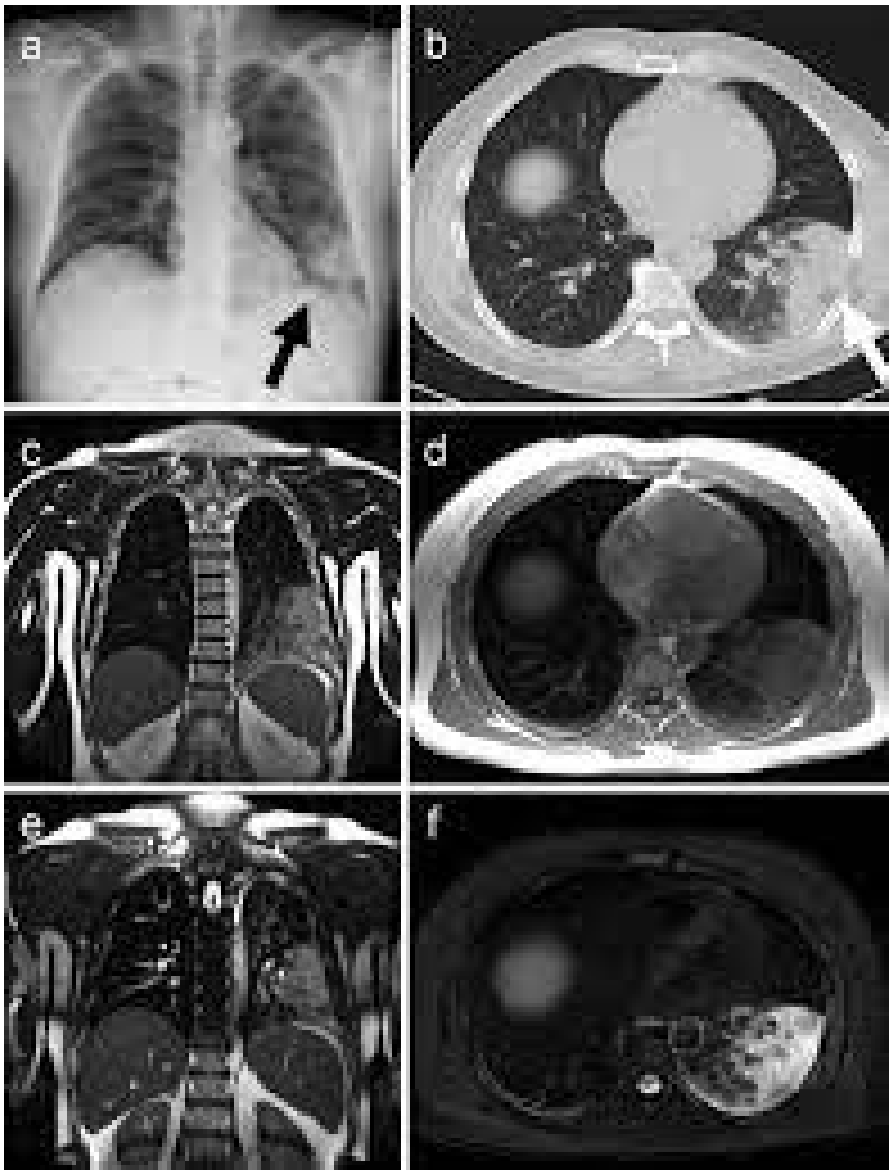

Lt Lower lung mass invading chest wall in different modalities

Basics of Cardiac Imaging

Cardiac Imaging Modalities

- ✓ **CXR :** Initial & basic for cardiac size & shape.
- ✓ **Echocardiography :** Anatomical & functional assessment.
- ✓ **Conventional Coronary Angiography.**
- ✓ **CT Coronary:** need CT 64 Slice & more
- ✓ **MRI Coronary**

…….. & Others

Normal Heart Anatomy in CXR

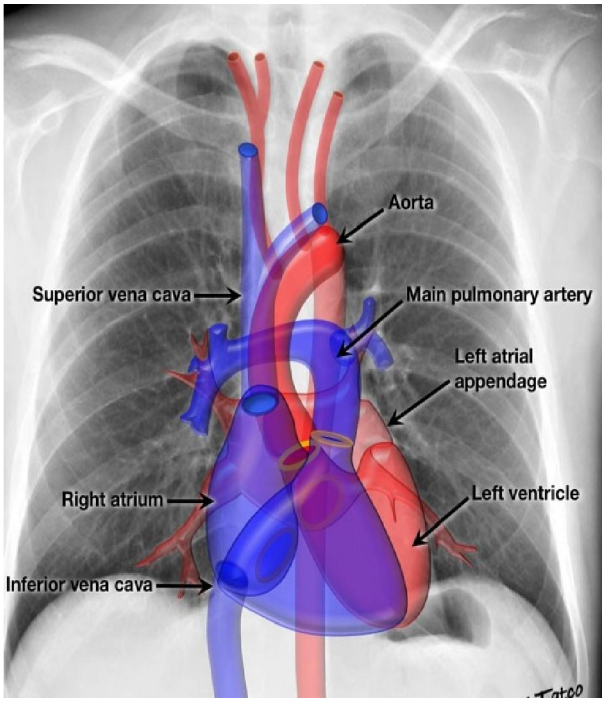

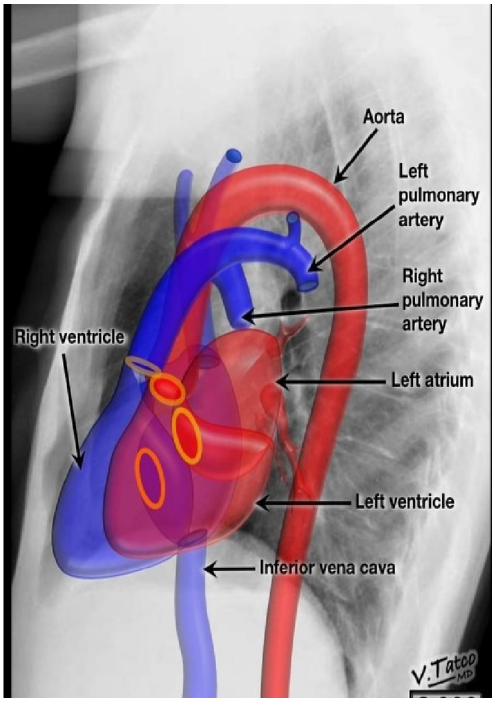

(Chest X Ray)

® **Abnormality of the heart in CXR may be :**

- Size
- Configuration (Shape & Position)

× **Abnormal Heart Position**:

- **Dextrocardia** : Heart only inverted
- **Situs Inversus Totalis** : both Heart & Gut are inverted

Heart is inverted in both (*Rt sided apex*)

To Differentiate: → **Side of Gastric bubble** (arrow)

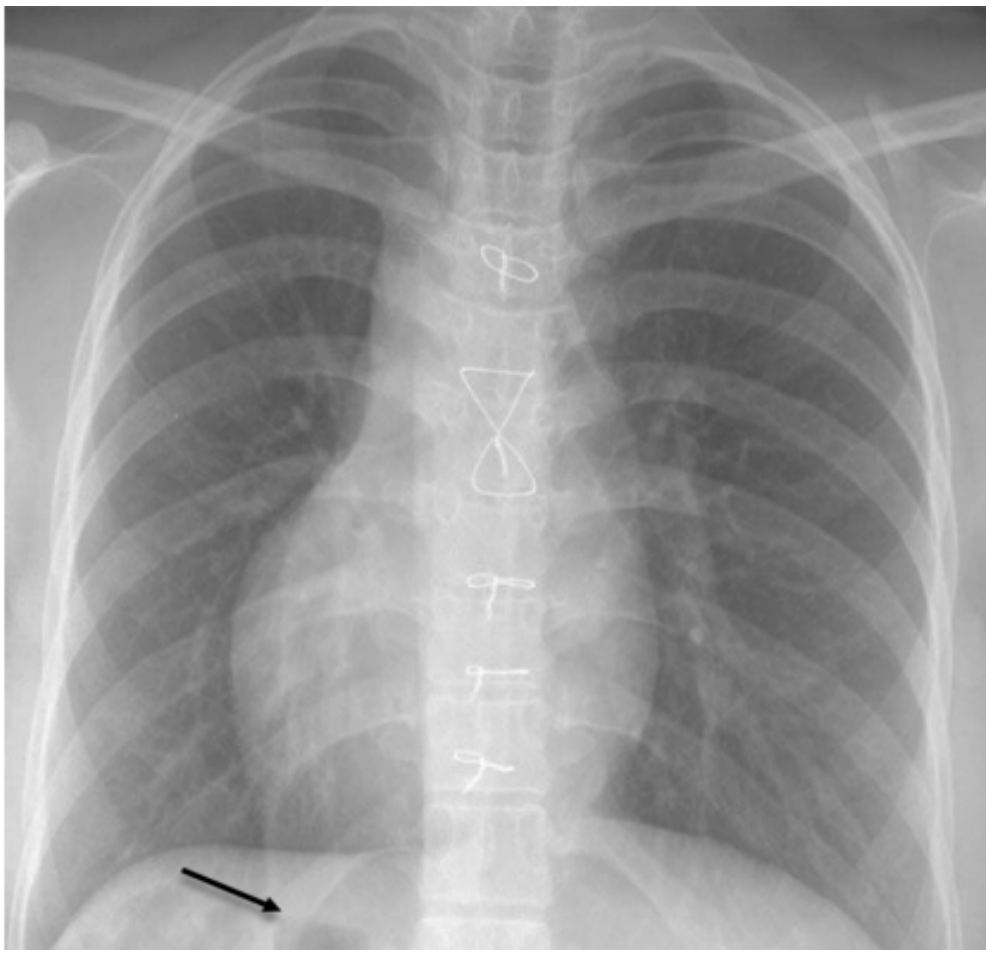

Situs Inversus Totalis

Dextrocardia

Notice that gastric bubble is in normal position, Heart only is rotated

× Abnormal Heart Size: Cardiomegally

(Enlarged cardiac shadow size)

✓ *How to assess cardiac size in CXR ?*

*By **Cardio-thorathic ratio***

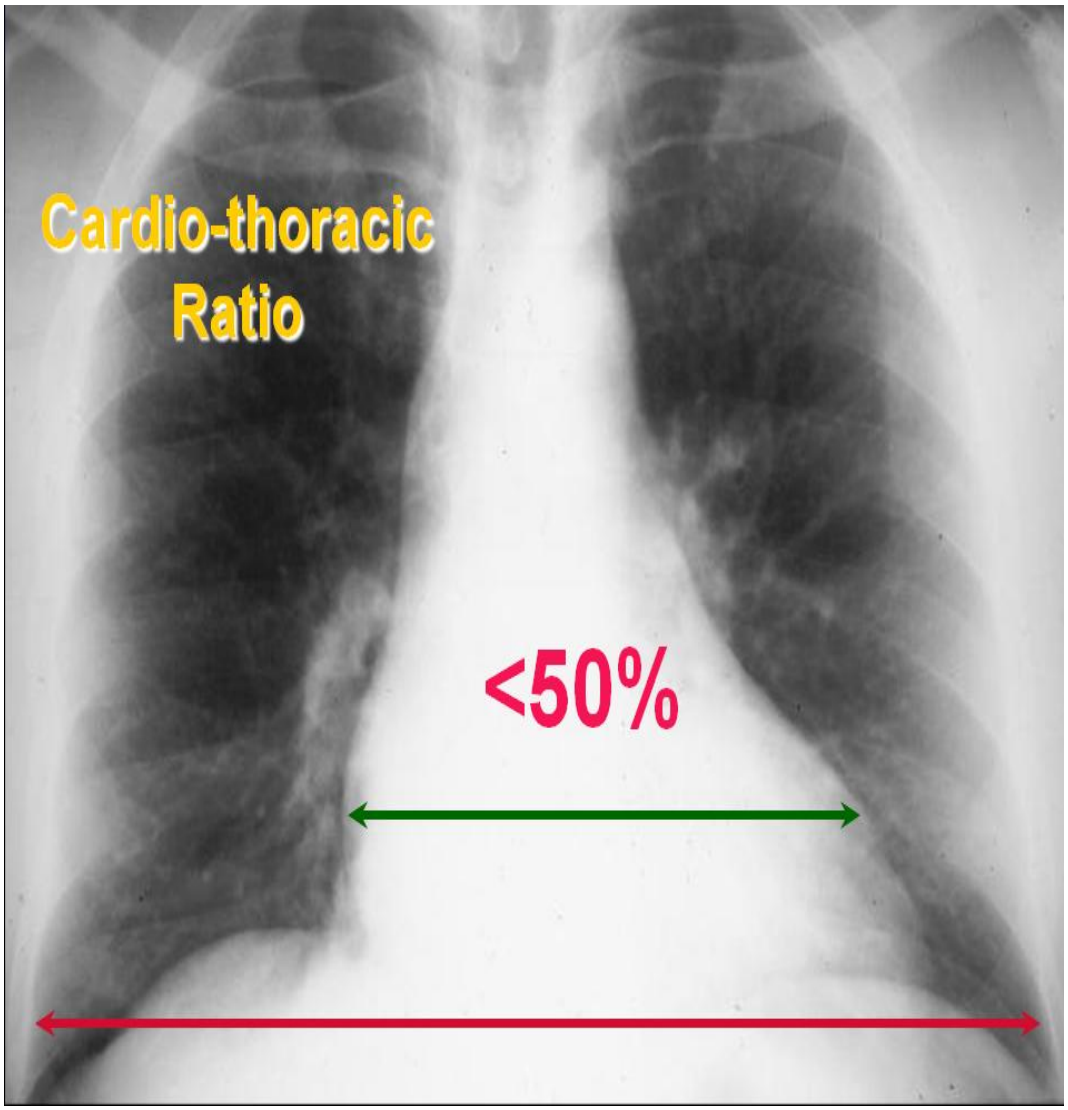

Normal

Cardio-thorathic ration < 50 %

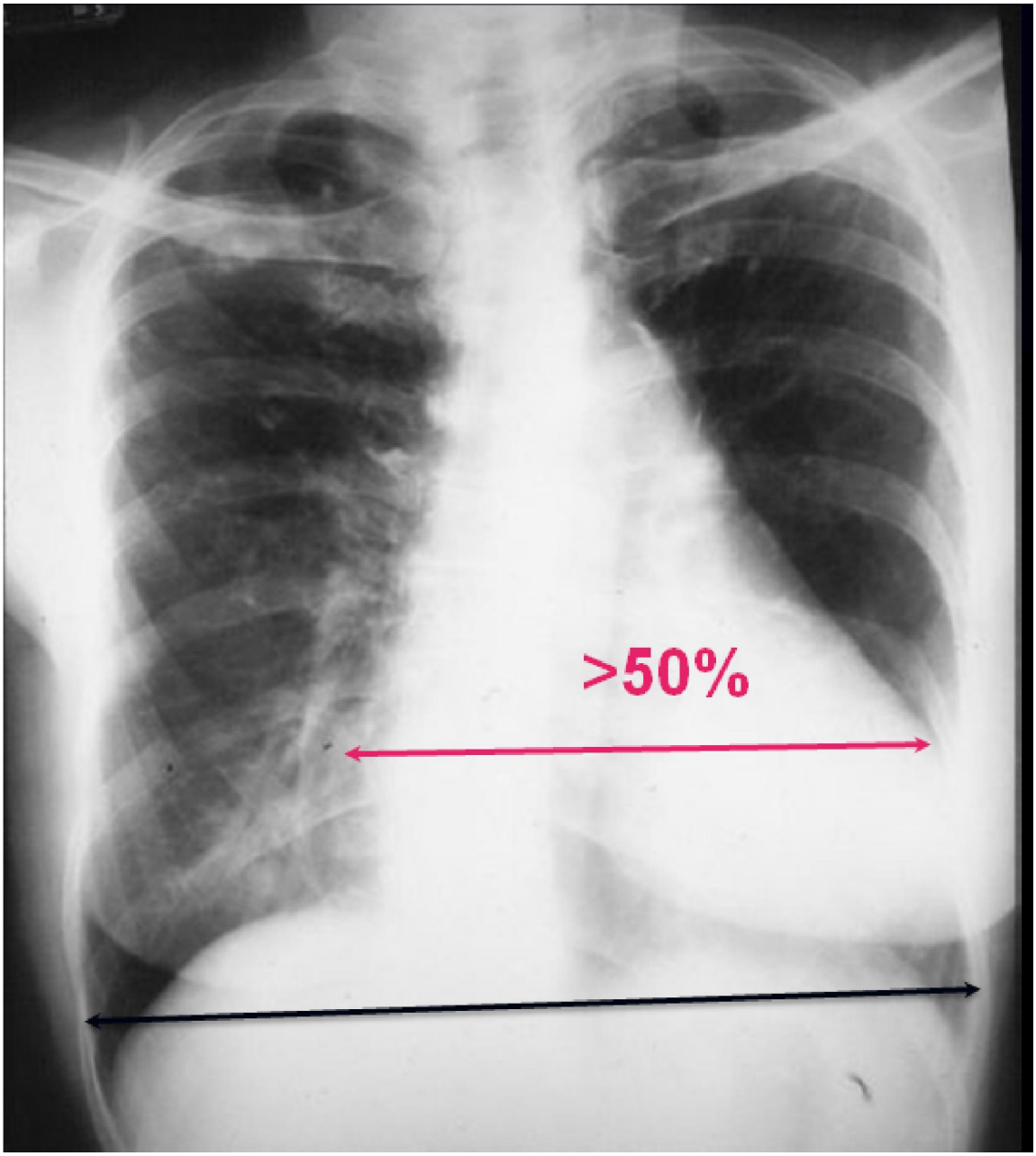

Cardiomegally

Enlarged Cardio-thorathic ratio

Abnormal Heart Shape:

Abnormality of heart shape in CXR is usually part of cardiomegally

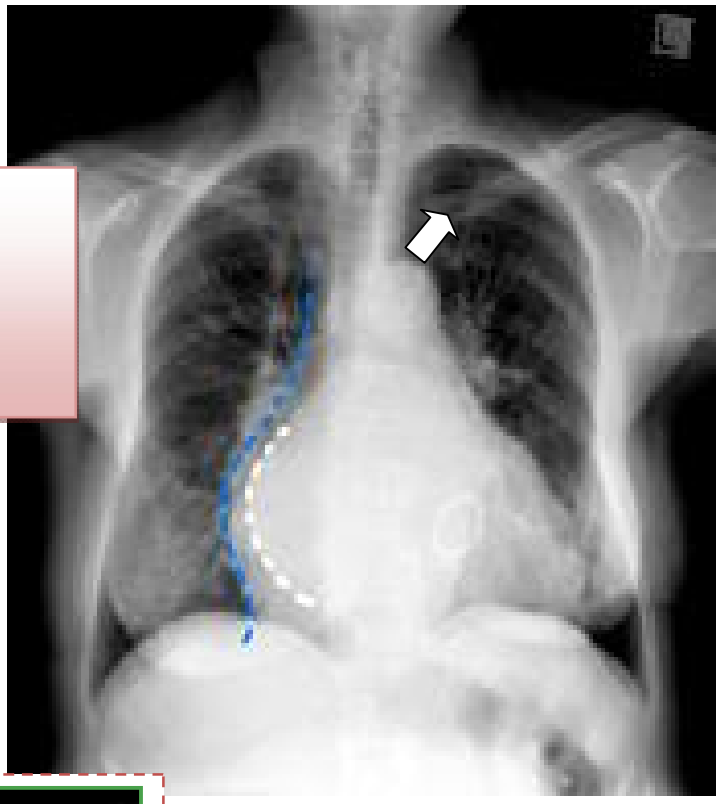

Lt Atrial Enlargement:

- ✓ Double Rt Border (Dashed lines)
- ✓ Straight Lt border
- ✓ Elevated Lt broncus (white arrow)

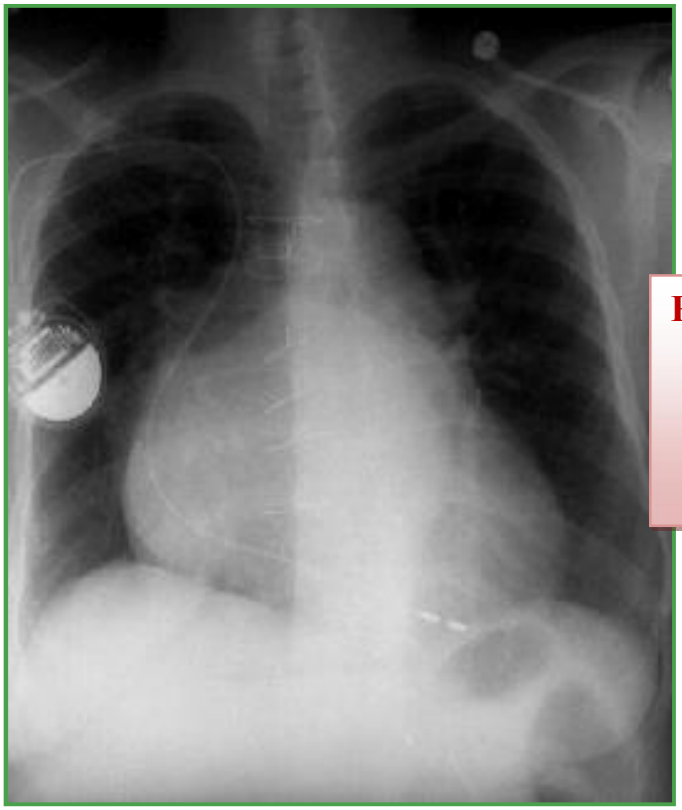

Rt Atrial Enlargement:

- ✓ Lateral prominence of the right cardiac border

Ventricular enlargement Rt or Lt ?

According to angle between Lt cardiac border & Lt copula

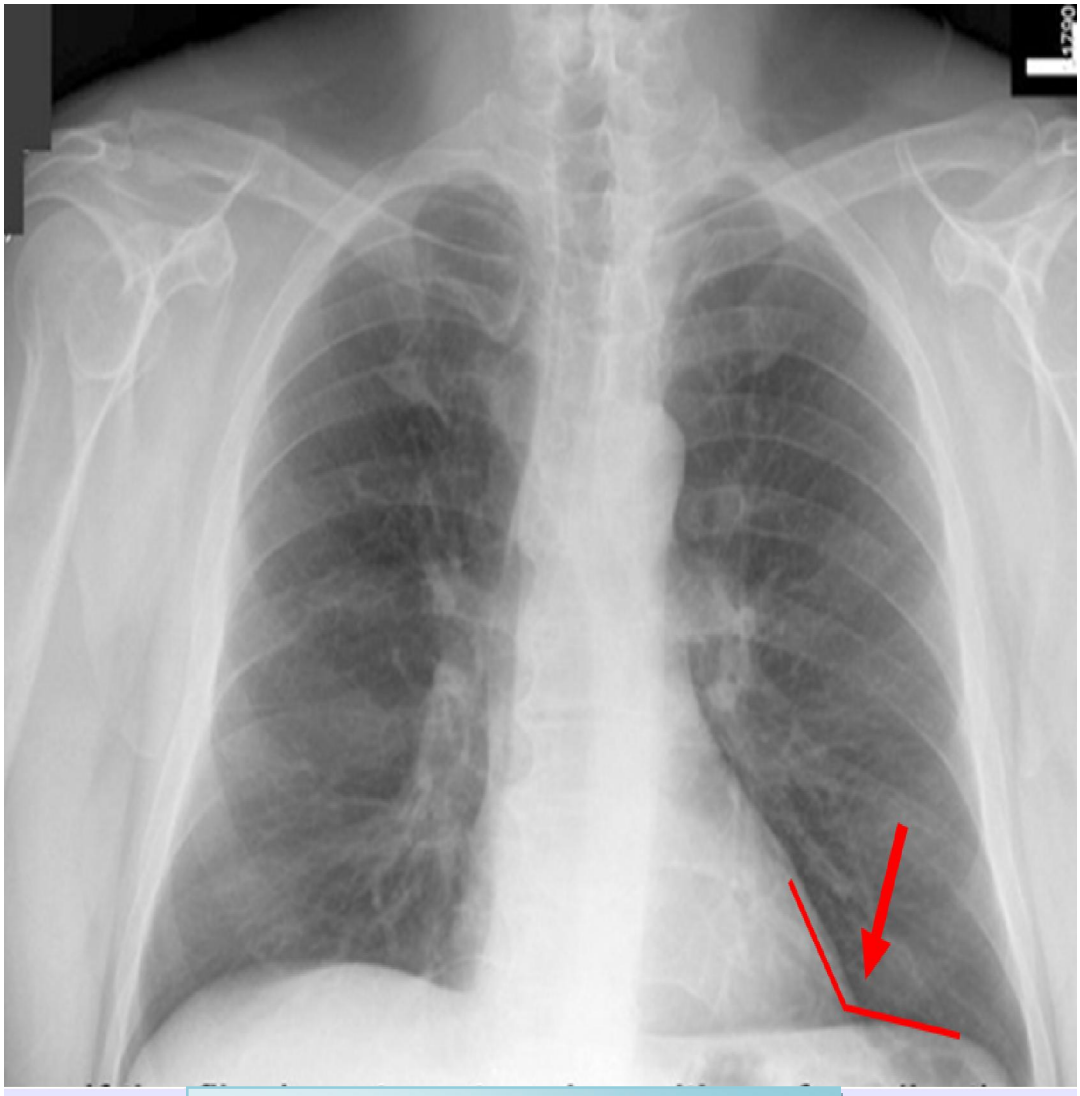

Lt Ventricular enlargement

→ ***Obtuse angle.***

"Looks like **small part of large circle"**

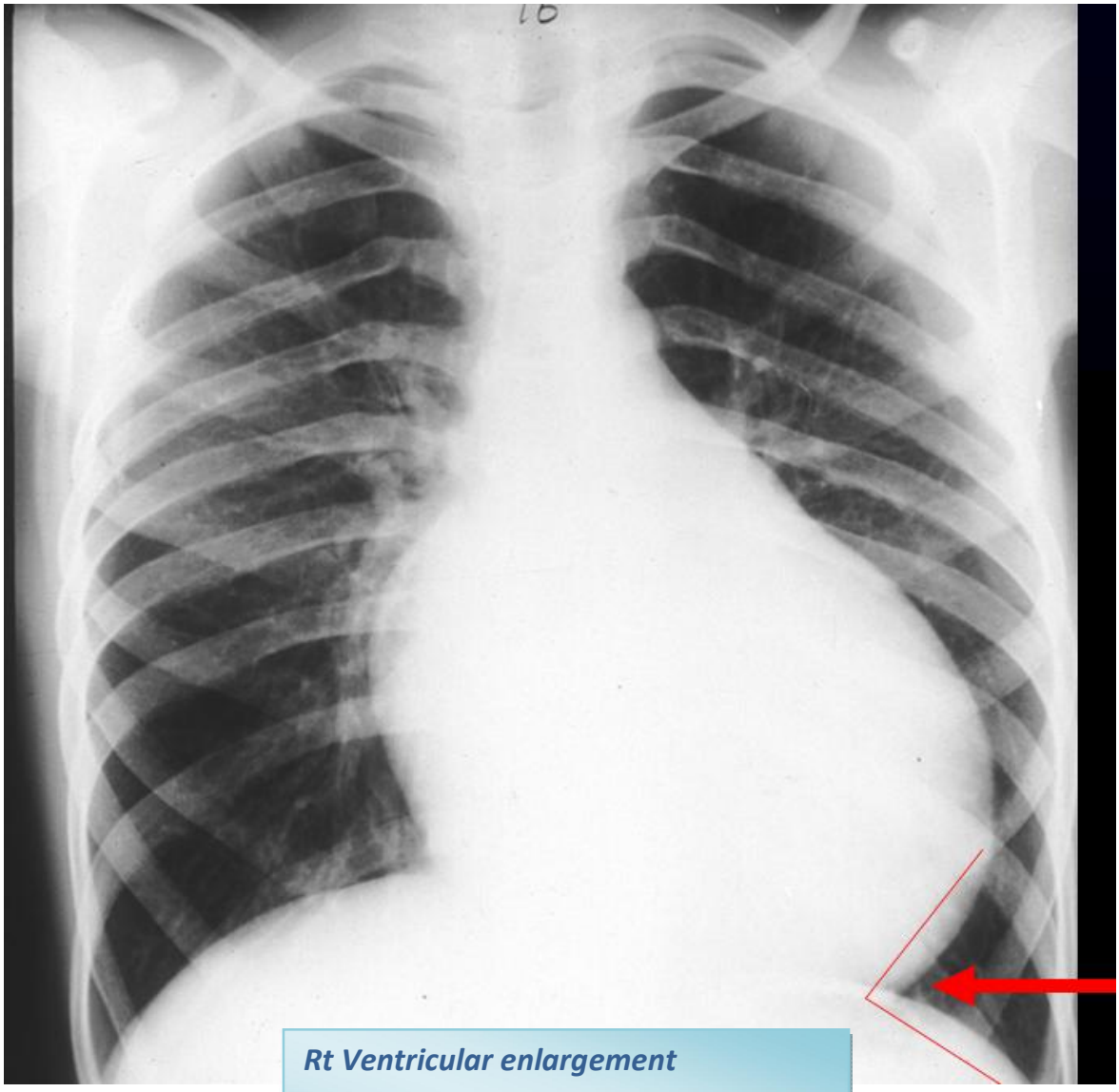

Rt Ventricular enlargement

→ ***Acute angle***

Looks like **large part of small circle"**

Fallots Tetralogy - Boot Shaped Heart

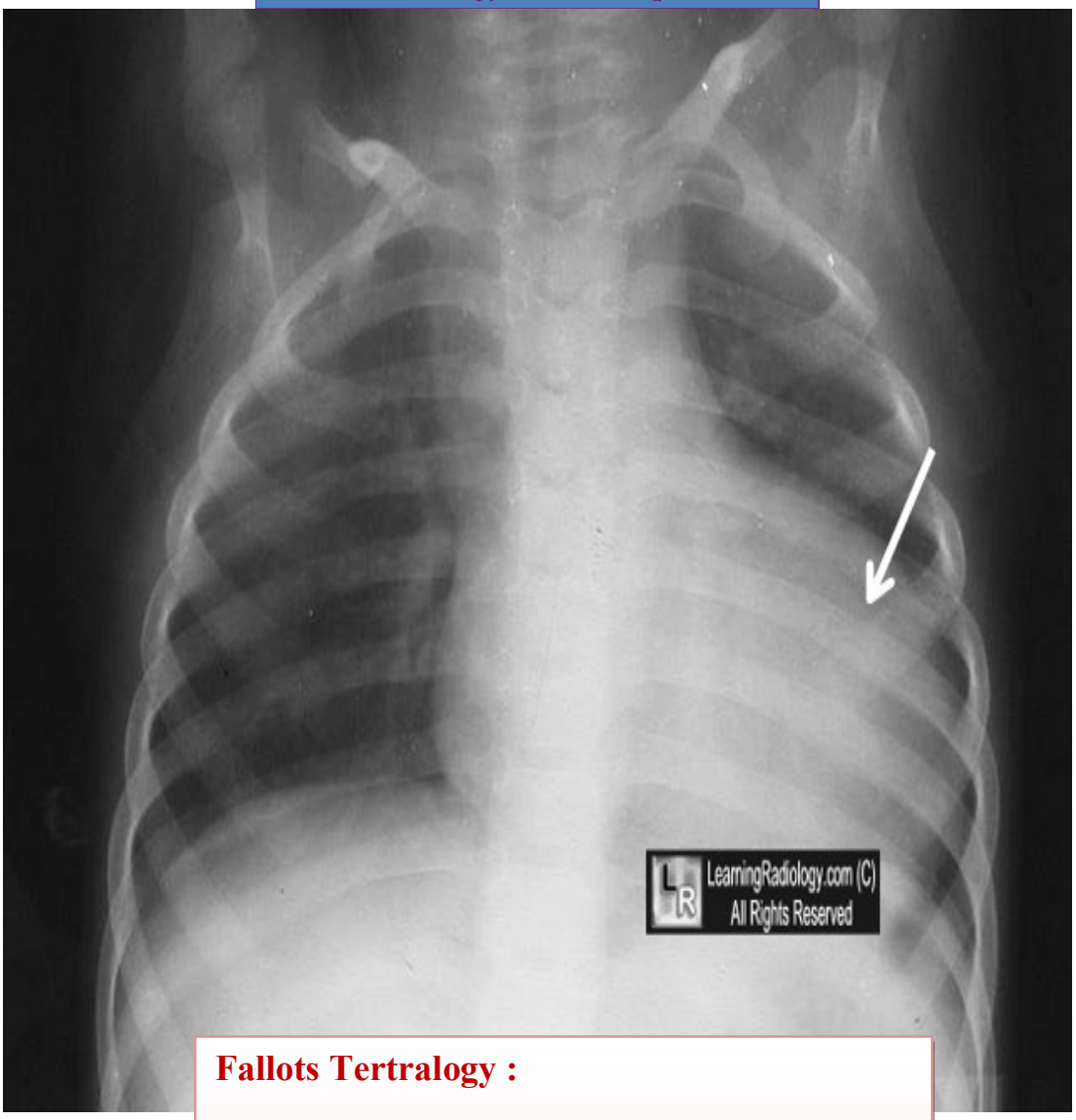

Fallots Tertralogy :

- ✓ Pulmonary Stenosis
- ✓ Rt Ventricular hypertrophy
- ✓ VSD
- ✓ Aorta override VSD

HINTS IN INTERPRETATON OF GREAT VESSELS ABNORMALITES

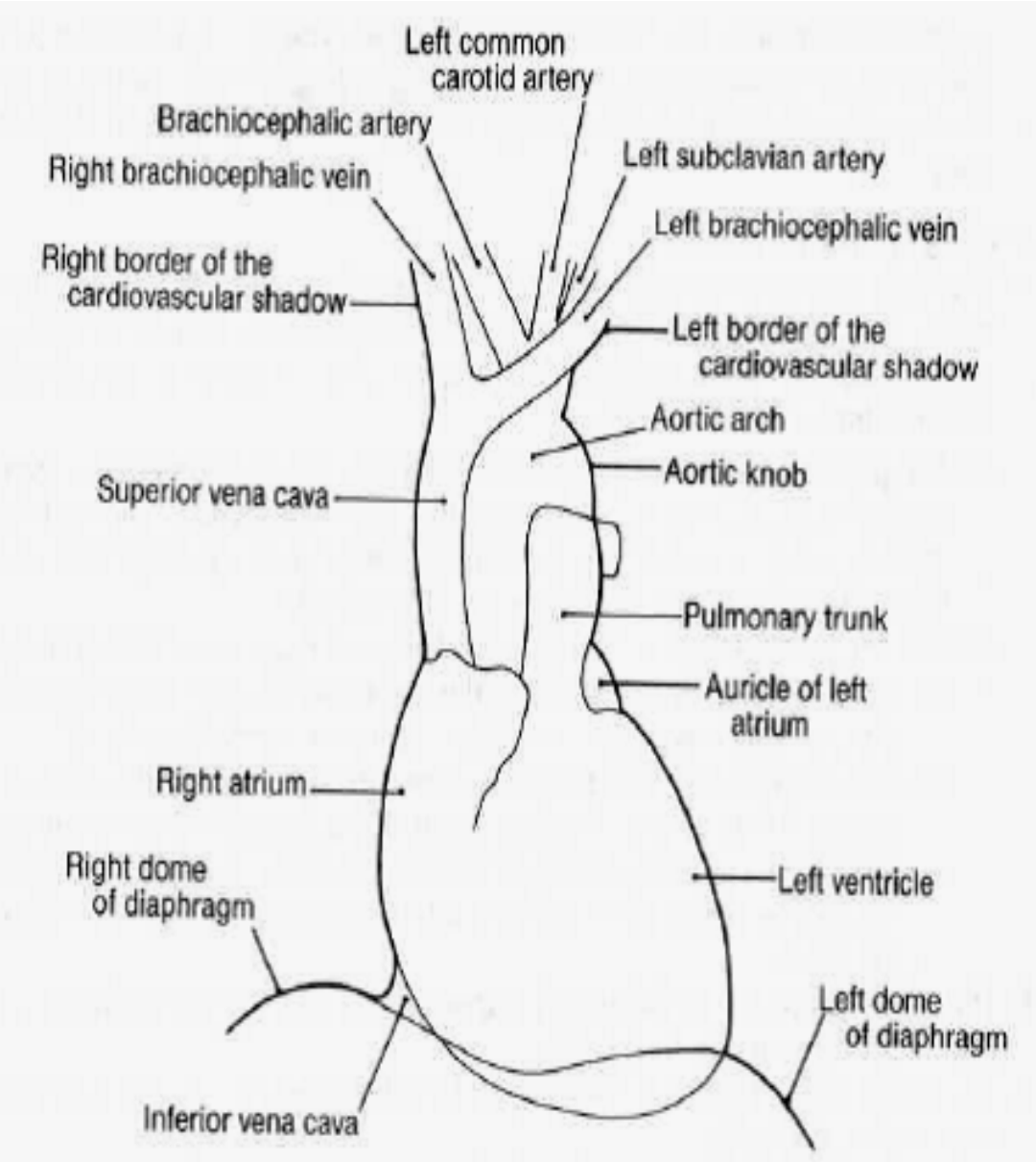

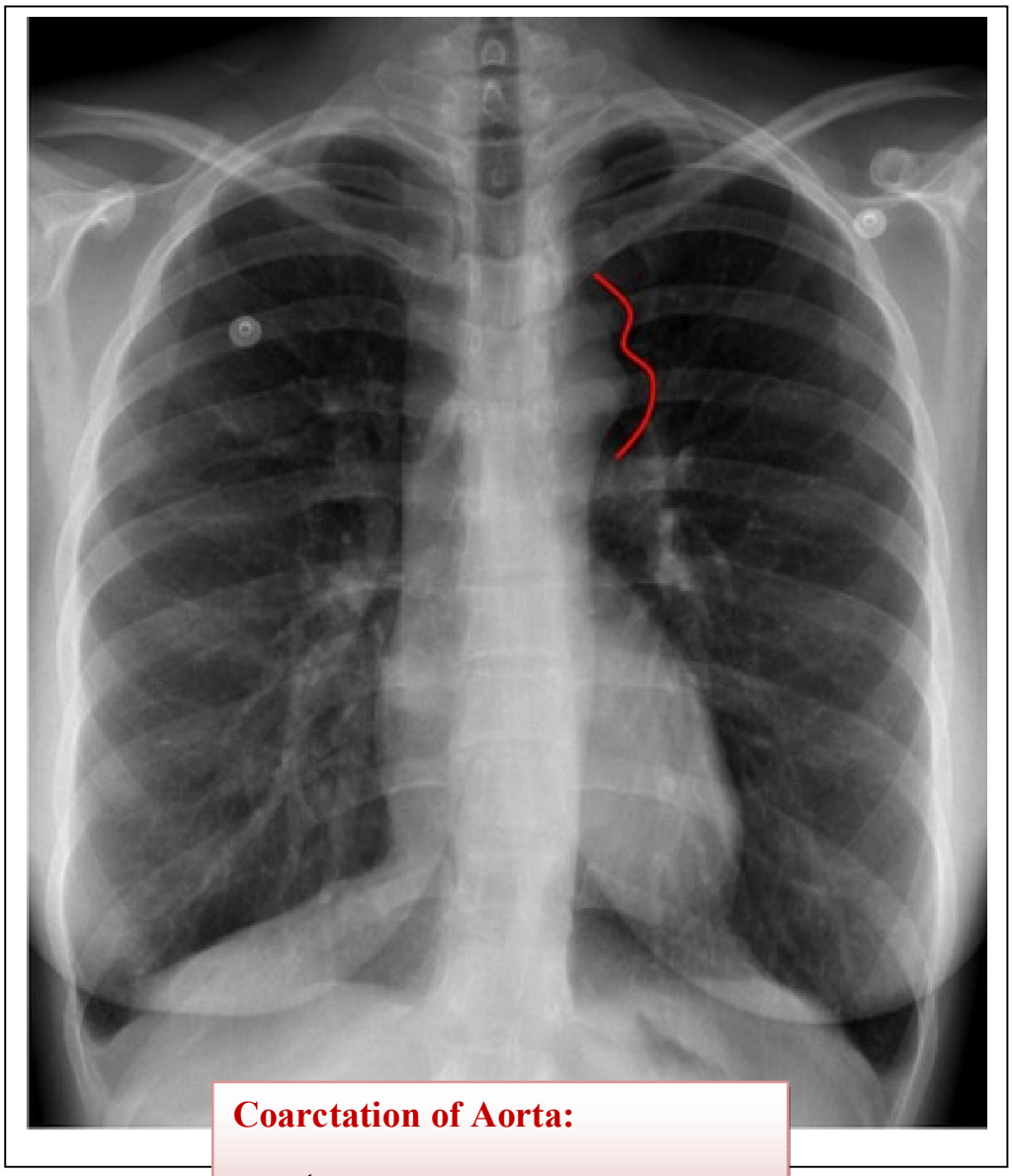

Coarctation of Aorta:

- ✓ **3 Sign**

Details are much more …… But

Undergraduates need to know basics only

Chest X ray Illustration Cases:

Pericardial Effusion
(Flask Shape Heart)

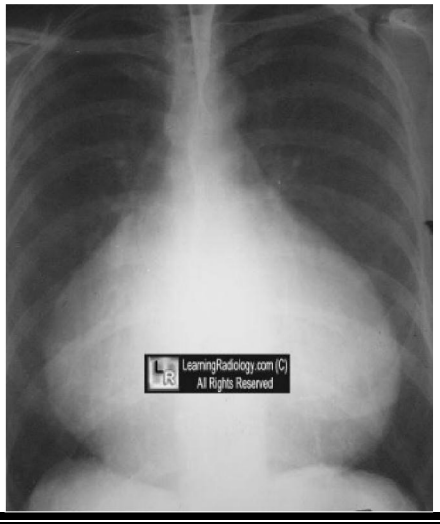

Fallot's Tetralogy
(Boot Shape Heart)

Dextrocardia

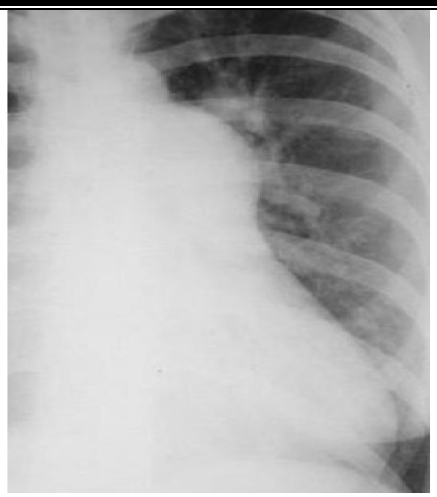

Pulmonary Hypertension

Enlarged Aortic Knob

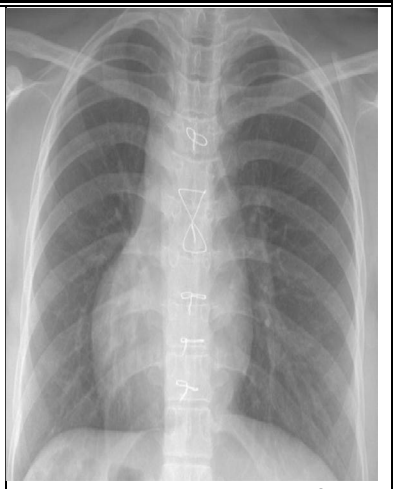

Situs Inversus Totalis

Coarctation of Aorta
3 Sign

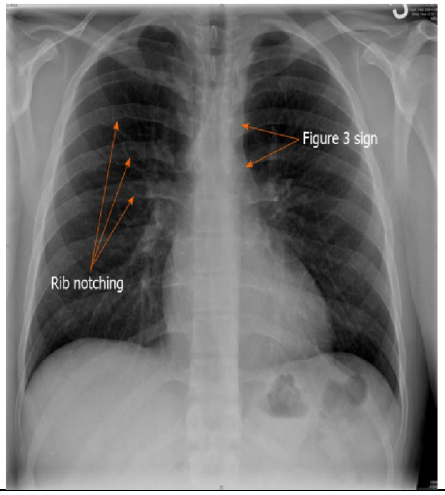

Pneumo-pericardium

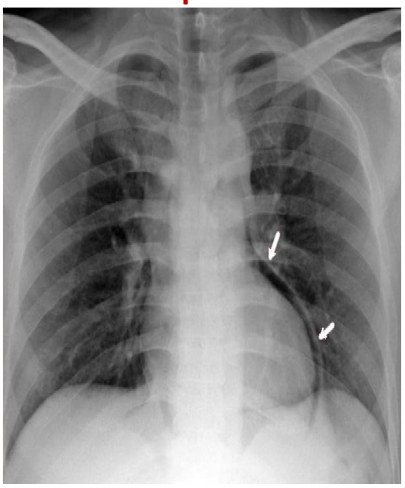

Pacemaker

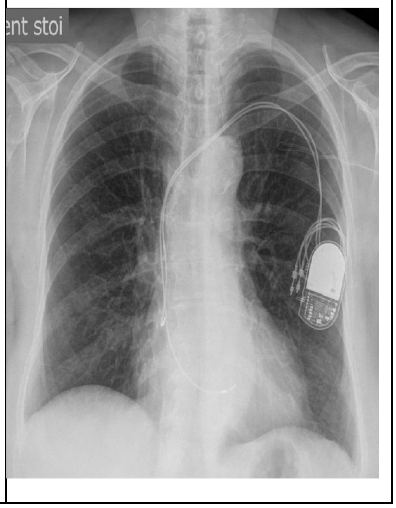

Basics of GIT Imaging

Hand outs of Scientific Society of Radiology

Is the main Source of this chapter

GIT Imaging Modalities

- ✓ **Abdominal US:** Initial & basic for cardiac size & shape.
- ✓ **Plane X ray** : for intestinal obstruction , perforated viscous
- ✓ **X ray with contrast:** (Barium Techniques).
- ✓ **CT** : Enhanced CT & CT techniques as virtual colonoscopy
- ✓ **MRI**

Plane X ray Abdomen – Erect Position

Multiple air fluid levels

Intestinal Obstruction

Barium examinations of the GIT

- ✓ Barium swallow ← (esophagus)
- ✓ Barium meal ← (stomach)
- ✓ Barium meal follow through ← (stomach , small intestine)
- ✓ Barium enema ← (colon)

Radiological terminology in barium studies

[1] Filling defect **[2]** Stricture **[3]** Diverticulum **[4]** Ulceration

Filling defect	Stricture	Diverticulum	Ulceration
A lesion inside or outside bowel lumen	segment luminal narrowing	saccular out pouching connected to bowel lumen	Injury of mucosa, visible when filled with barium
		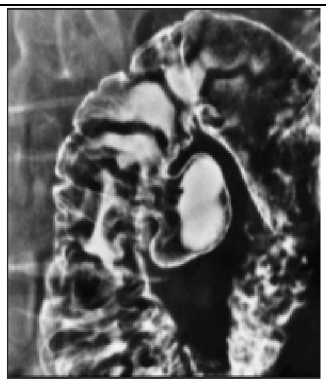	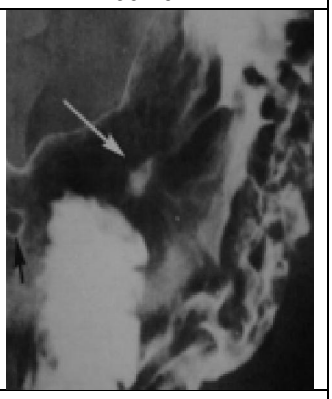

Esophagus (Barium swallow)

- ✓ The patient swallows **barium paste**
- ✓ The flow is observed on a T.V. monitor and films are taken
- ✓ With the oesophagus full to show **filling defects**
- ✓ With oesophagus empty to show the **mucosal folds**

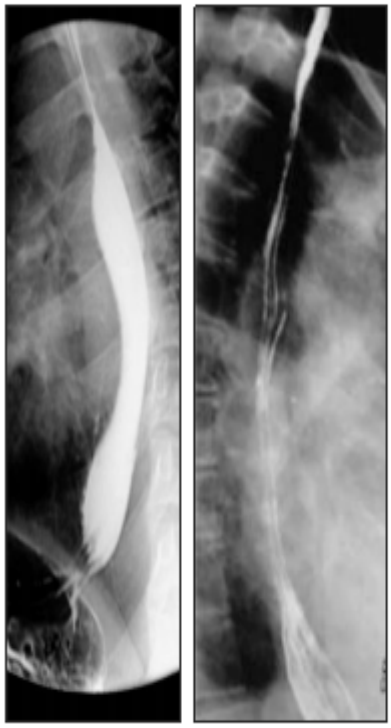

Normal barium swallow showing normal esophageal caliber with no evidence of filling defects, ulcerations, strictures or diverticulae

Esophageal abnormalities

Filling defect	Stricture		Diverticulum
× **Benign :** as lyomyoma × **Malignant :** carcinoma	× Corrosive × Peptic	× Achalasia × Malignant	-Zenker's -Mid esophageal -Epi - phrenic

1- Esophageal Stricture

× Corrosive	× Achalasia	× Malignant
Long segment starts at level of **aortic arch** × Accidentally in children × Suicide in adults	primary esophageal motility disorder	× Anywhere in oesophagus × Commonly seen in the middle third × Lower third lesions may simulate achlasia
Radiographic appearance : –long, smooth outline –Upper end is funnel shaped and tapers into normal oesophagus –Lost mucosal pattern	**Smooth tapering** of distal sophageal segment , with marked proximal esophageal destination (**Parrot Beak sign**)	stricture with esophageal overhanging edges → typical **apple core** configuration
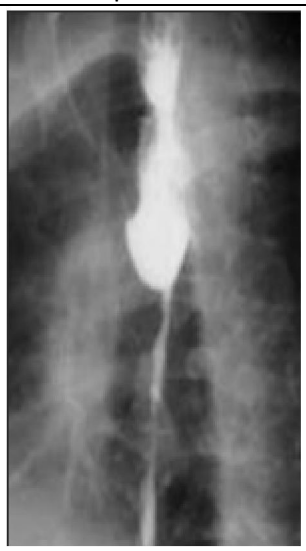		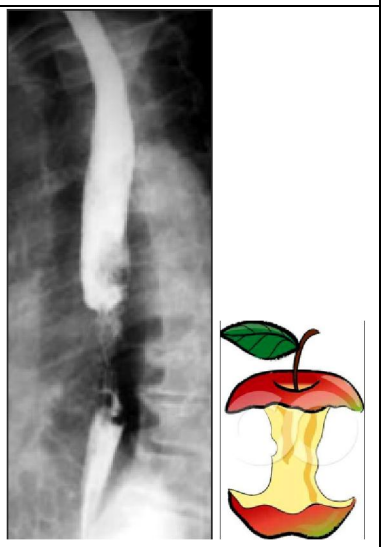

[2] Filling defect

× **Benign** lesion as : liomyoma or

× **Malignant** lesion: carcinoma or lymphoma.

In all cases endoscopic evaluation is needed for biopsy taking

[3] Diverticulum

Barium swallow showing: a small mid-esophageal diverticulum

Barium swallow: diverticular out poaching in the neck at junction of hypopharynx & upper esophagus

Stomach and Duodenum (Barium meal)

- ✓ Patient **fasting for 6 hours** before the exam
- ✓ Patient drinks **fluid barium**
- ✓ **Different views** for the stomach are taken by changing the patient's position

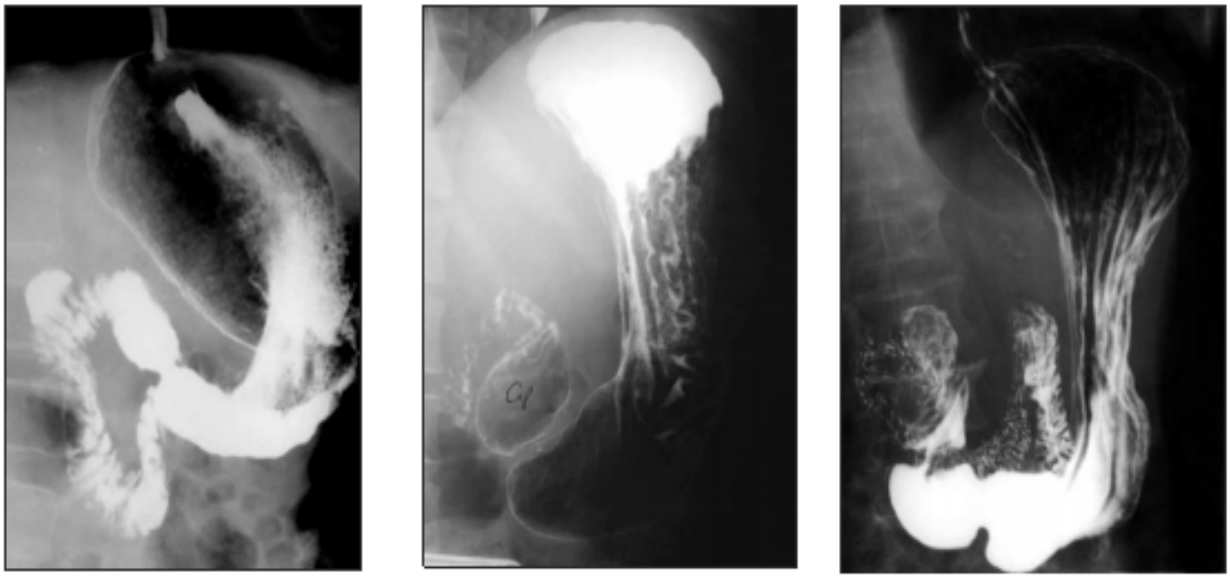

Normal barium meal: In the erect position, the stomach will appear 'J' shaped. The gastric fundus will normally contains gas bubbles. The gastric body and pylorus will be filled with barium

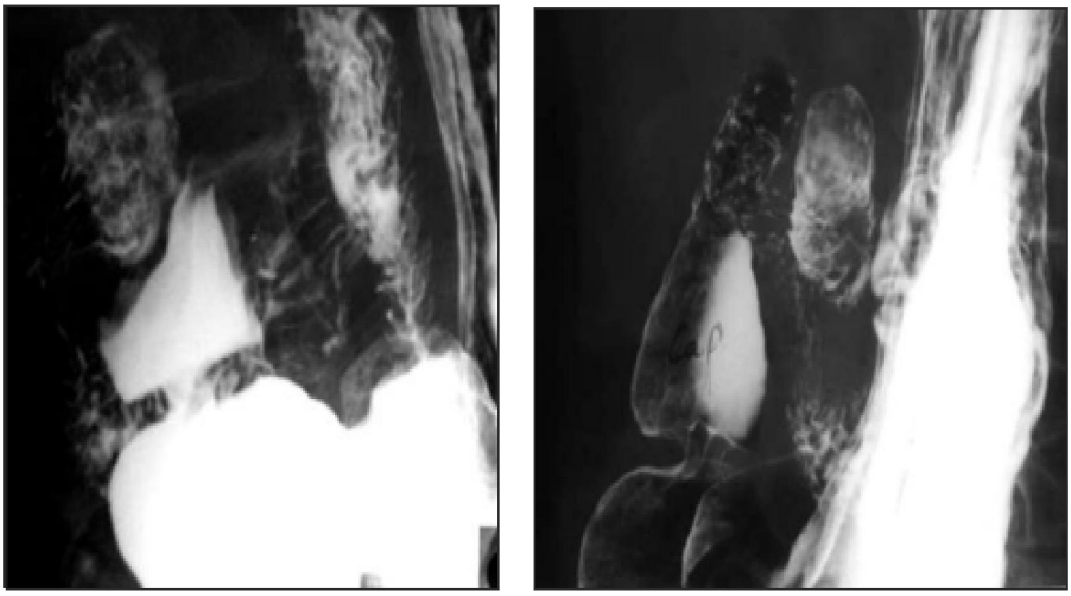

Normal duodenal cap: Spot view of barium meal showing the normal triangular shape of the duodenal cap which should be radiographed when it is filled with barium (left image) and while filled with air (right image)

Stomach abnormalities

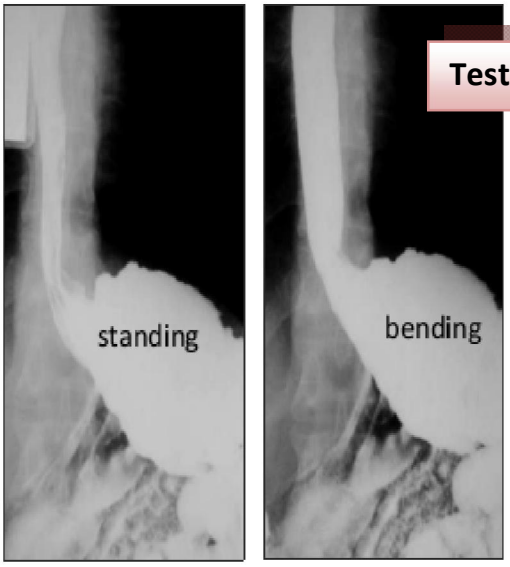

Testing for Reflux

Barium swallow while standing showing normal esophagus. When the patient bends to pick up something at the end of the examination table reflux of barium into the lower esophagus is noted

Hiatus hernia

Herniation of the stomach through the esophageal hiatus above the diaphragm

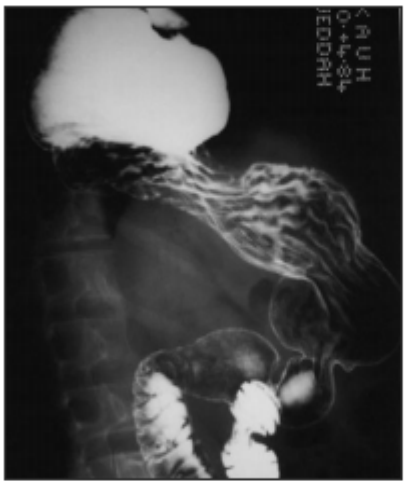

Hiatus hernia: Barium meal examination showing herniation of the gastric fundus above the diaphragm

[A] Filling defect

- Gastric bezoar
- Benign lesions
- Malignant lesions

Bezoars Mobile intra-gastric F.B surrounded by Barium

- Tricobizoar made of hiar
- Phytobizoar made of plant fibres
- Pharmacobizoar made of drugs

lling defects

n between benign and malignant filling defects is accurate on radiological bases. Endoscopy is biopsy taking

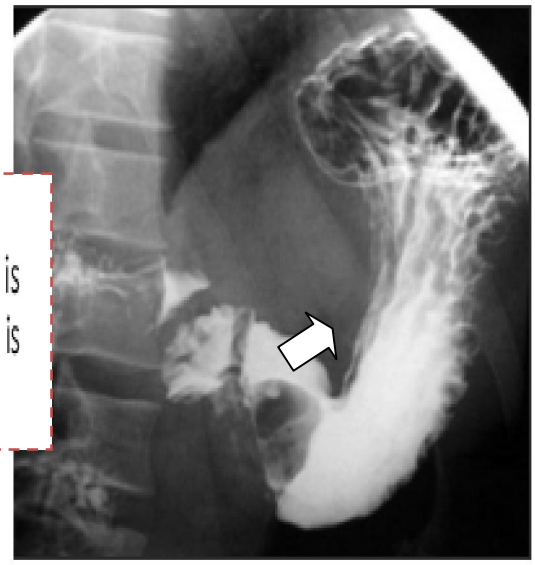

Linitis plastica

Malignant lesions produce irregular filling defect with destruction of the normal mucosa.

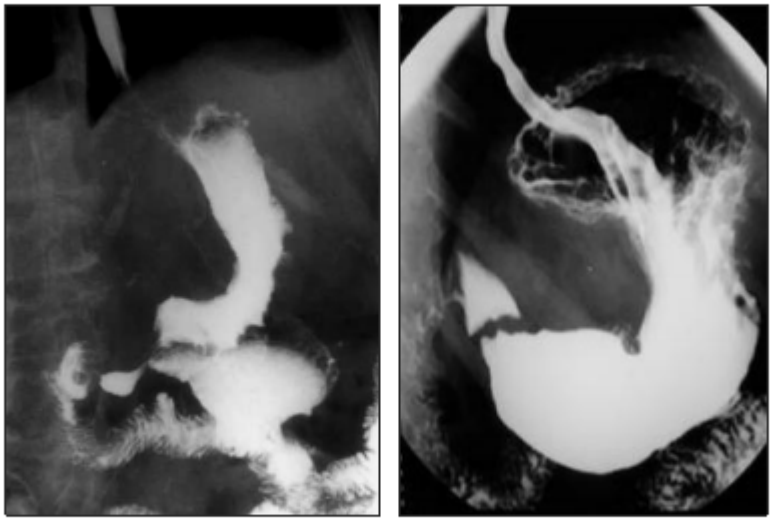

Linitis plastic: Barium meal showing marked reduction of the gastric lumen with irregular outlines compared to the normal stomach seen in the right image

Acute duodenal ulcer: Double Contrast barium meal study demonstrating an ulcer in the duodenal bulb with radiating mucosal folds. This was confirmed at endoscopy, performed 3 weeks later

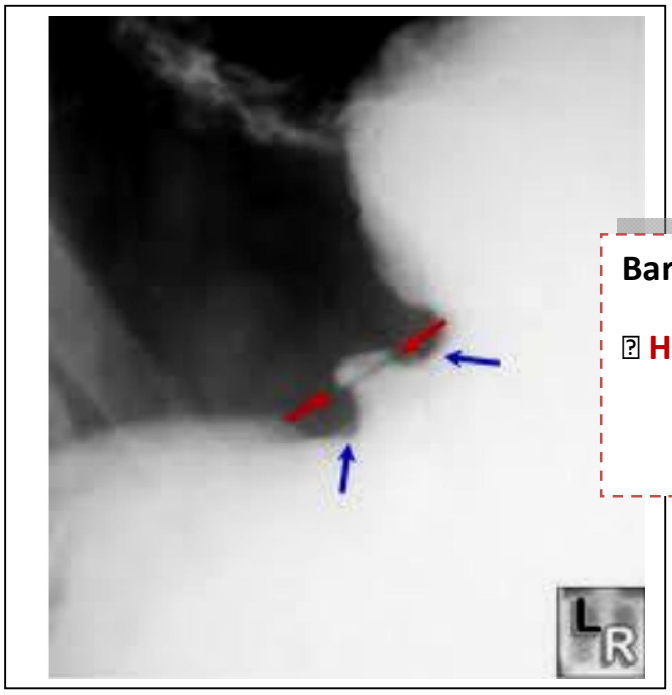

Barium Meal

- **Hampton line sign**

  ‹sure sign of benign peptic ulcer

Chronic duodenal ulcer

Duodenal ulcer with scarring and marked deformity of the base of the duodenal bulb after healing of a duodenal ulcer.

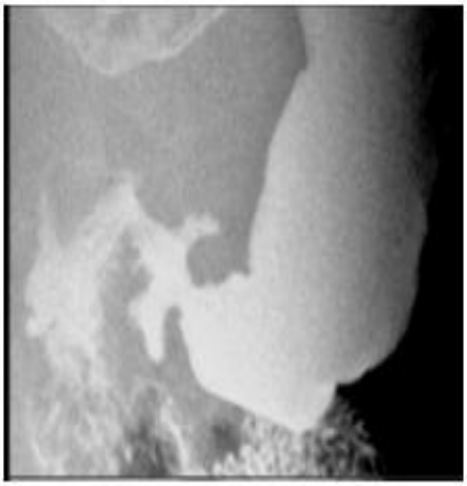

Chronic duodenal ulcer: Barium meal showing the classic trefoil deformity of the duodenal cap due to fibrosis resulting from healed ulcer

Small intestine abnormalities

Barium meal follow through

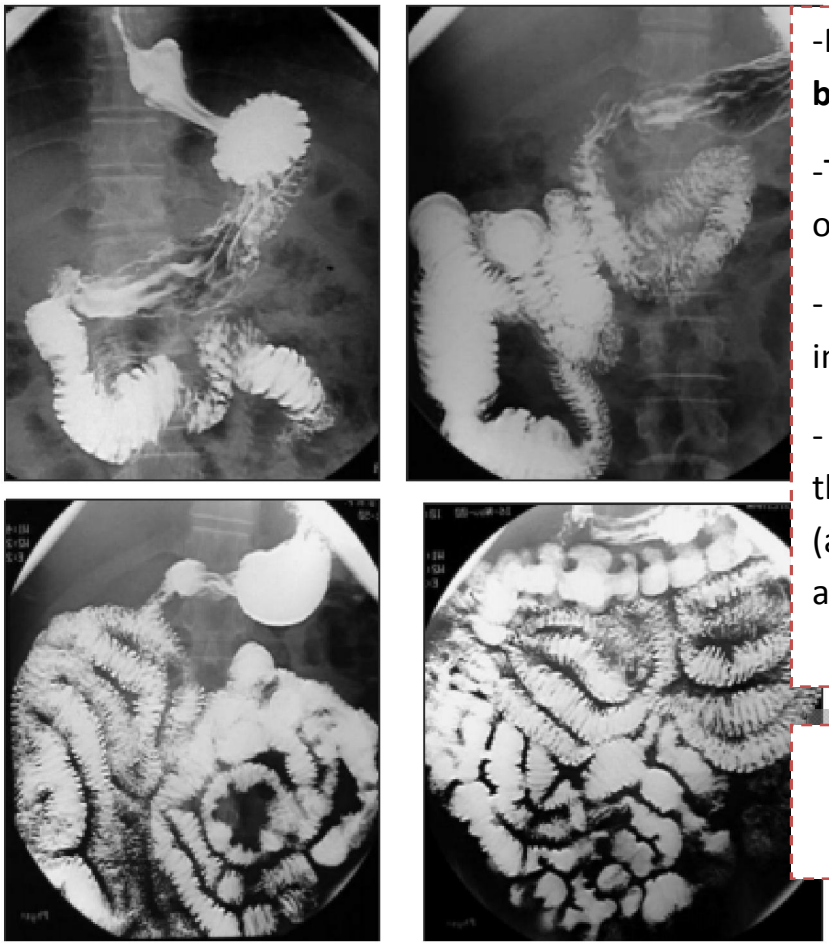

-Patient drinks **200-300 ml barium**.

-The barium flow is observed

- films are taken at regular intervals

- until the barium reaches the ascending colon (average time is 2-3 hours after barium intake).

Normal

Small Intestinal series

Corhn's disease

Sub mucosal lymphoid tissue hyperplasia → thickening and rigidity of the affected segment → luminal narrowing = Stricture

Crohn's disease : Spot view from a small-bowel follow-through study showing irregular luminal narrowing of the terminal ileum with ***rose thorn*** appearance due to linear longitudinal and transverse ulcerations Also note the displacement of the involved loop away from the normal small bowel secondary to mesenteric inflammation and fibro fatty proliferation

Large Intestine (Barium Enema)

Barium enema

- ✓ is a valuable diagnostic tool
- ✓ It helps detect abnormalities in the large intestine .
- ✓ Barium enema, along with colonoscopy, remains standard in the diagnosis of colon cancer, ulcerative colitis, and other diseases of the colon.
- ✓ **Colonoscopy** allows both therapeutic resection of mucosal lesions as well as diagnostic biopsy.

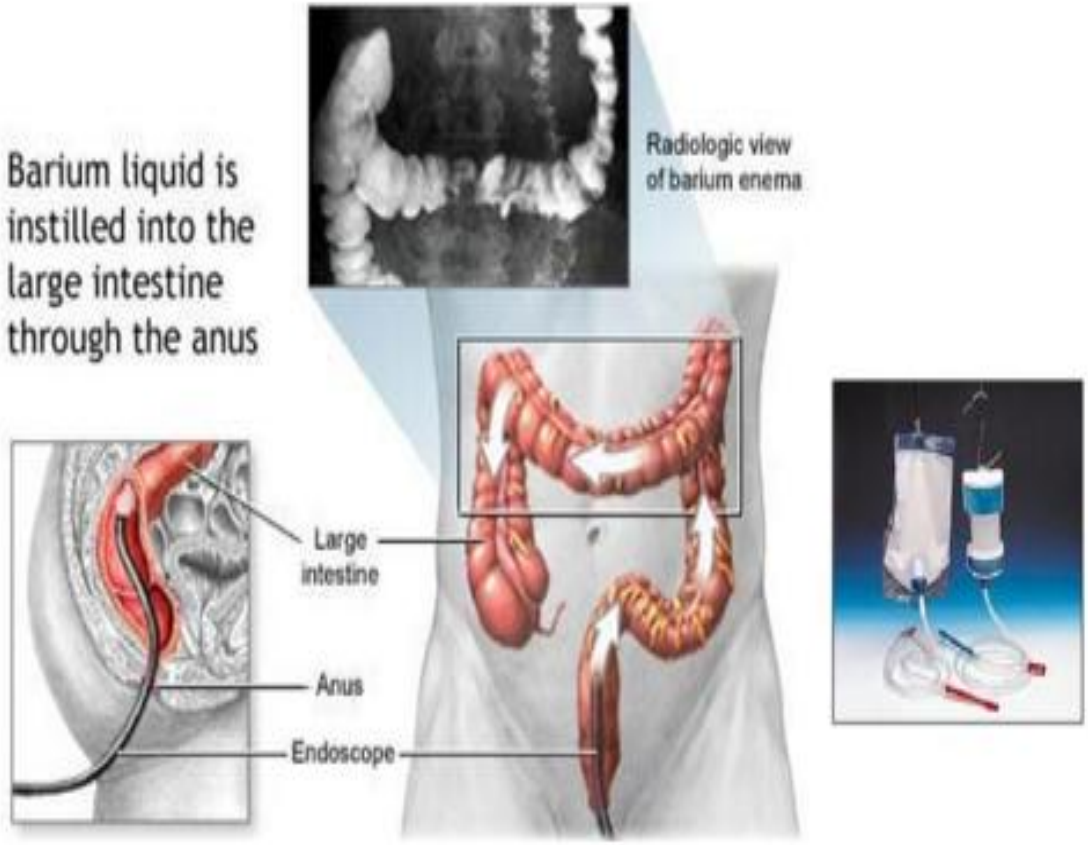

Normal barium enema:

Double contrast enema showing the normal appearance

Colonic diverticular disease: Barium enema examination showing few colonic diverticulae mainly affecting the sigmoid and descending colon with no evidence of complications

Ulcerative colitis: Double contrast barium enema shows a featureless descending and sigmoid colon, lacking normal haustral marking. No evidence of stenoses , masses or fistula formation. Normal ascending and transverse colon appear normal.

Sigmoid carcinoma
Barium enema study demonstrating an "apple core" lesion most consistent with carcinoma of the bowel.

Cancer colon: Barium enema examination showed malignant stricture with typical apple core configuration seen involving the distal part of the transverse colon [arrow]

Don't Forget:

- ✓ Barium studies are **contraindicated** in intestinal obstruction & suspected perforated gut.
- ✓ Barium is a highly irritant chemical material, if contact peritoneum → **sever chemical peritonitis**.
- ✓ **Abdominal US** , is the basic & initial modality for assessment of most of GIT abnormality.
- ✓ **Consult radiologist to chose the most suitable modality for the case.**

Basics of UT Imaging

Urinary Tract Imaging Modalities

- Ultrasonography (US)
- Plain kidney, ureters and bladder (KUB / PUT)
- Intravenous urogram (IVU)
- Cystography and ureathrography
- Computed tomography (CT) scan
- Magnetic resonance imaging (MRI) scan
- Nuclear medicine
- More invasive tests

Ultrasonography (US)

- ✓ Non-invasive
- ✓ Real time imaging
- ✓ No radiation hazards
- ✓ No contrast media

Normal renal sonogram

® **Diagnostic value**

- ✓ **Parenchymal changes** assessment
- ✓ **UT calculi** (Stones) detection
- ✓ UT **obstruction**
- ✓ Renal & bladder **masses** or Cysts
- ✓ **Congenital anomalies**
- ✓ Doppler assessment of the **renal vessels**

Plain UT (PUT)

Diagnostic value

- ✓ Radioopaque calculi
- ✓ Calcifications
- ✓ Gas pattern
- ✓ Bony abnormalities

Normal PUT

Intravenous urography (IVU)

Requirements:

- ✓ Fasting **4-6 hours** , good hydration is essential
- ✓ Adequate bowel preparation
- ✓ Renal function tests [serum creatinine level below 3]
- ✓ Non ionic contrast media are used
- ✓ to guard against contrast nephropathy

Diagnostic value:

- ✓ Show the renal function
- ✓ UT obstruction
- ✓ Renal an bladder masses
- ✓ Congenital anomalies

Contraindications:

- × Renal impairment
- × Hypersensitivity to contrast media

Normal IVU

IVP series

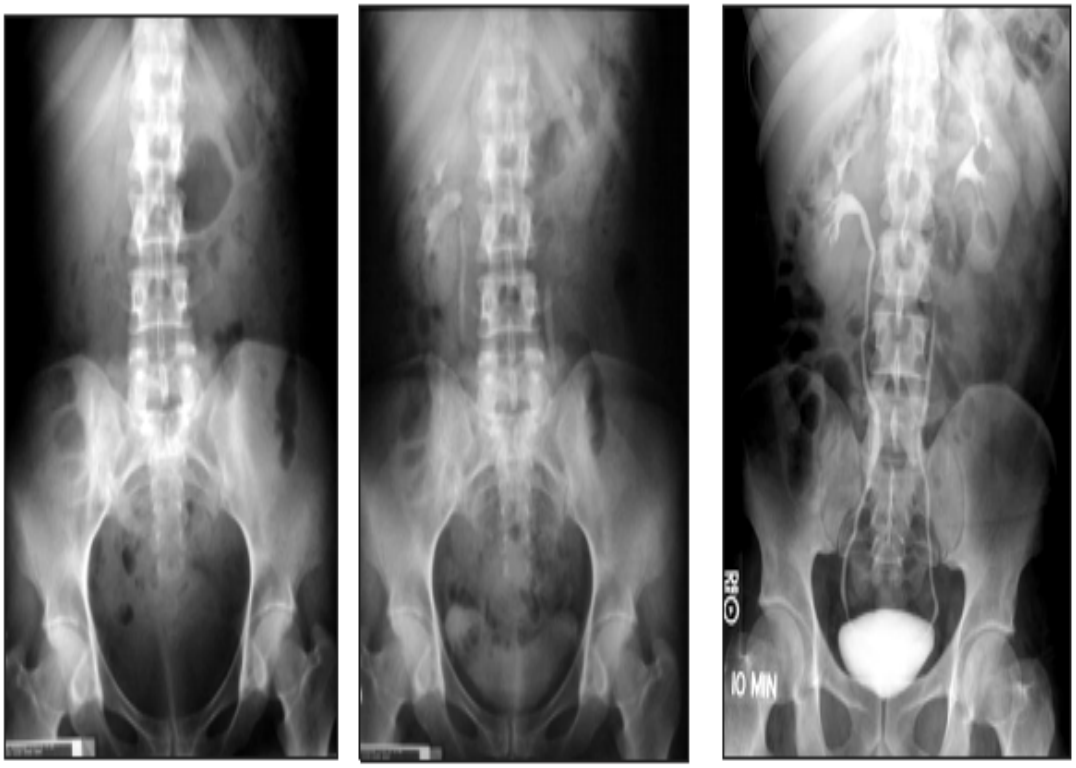

PUT showing no radiopaque calculi: IVP showing normal renal function with normal appearance of both pelvicalyceal systems, ureters and urinary bladder

Computed tomography (CT)

Advantages:

- ✓ More sensitive

Requirements:

- ✓ Fasting 4-6 hours
- ✓ May need bowel preparation
- ✓ May use contrast media

Don't Forget : radiation hazards

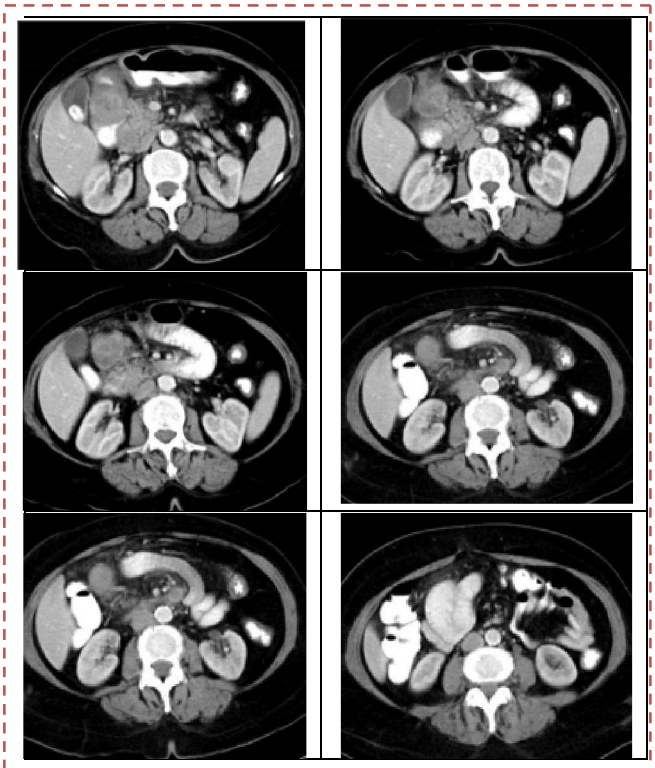

Enhanced CT , showing

normal renal configuration and function

Diagnostic value

- ✓ Accurate Detection of UT calculi
- ✓ UT obstruction
- ✓ Renal an bladder masses
- ✓ Differentiates masses cystic/solid
- ✓ Congenital anomalies
- ✓ CT angiography

Magnetic resonance imaging (MRI)

- ✓ Functional & Morphological imaging

Indications :

- ✓ Risk of contrast nephropathy
- ✓ Allergy to contrast agents

Requirements :

- ✓ Fasting 4-6 hours
- ✓ No bowel preparation
- ✓ May use contrast media
- ✓ No radiation hazards

MR urography **without** IV contrast injections

× UT Pathologies

Diagnosis of UT pathology

- Stone disease
- UT neoplasms
- UT infection
- UT trauma
- Miscellaneous lesions
  - Congenital lesions
  - Vesico – ureteric reflux
  - Urethral lesions
  - Reno-vascular hypertension

Renal Stones:

- ✓ **Radioapque** → Seen in US / PUT
- ✓ **Radiolucent** → Seen in US / IVU (Obstructive effect)

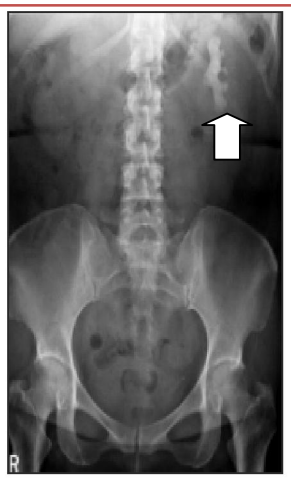

Large stage- horn left renal stone

Small left renal stone

Multiple large urinary bladder calculi

Radiolucent left renal stone seen

occupying the renal pelvis with no back pressure effect

IVP showing

Distended left pelvicalyceal system and ureter proximal to a **suspected distal ureteric stone**

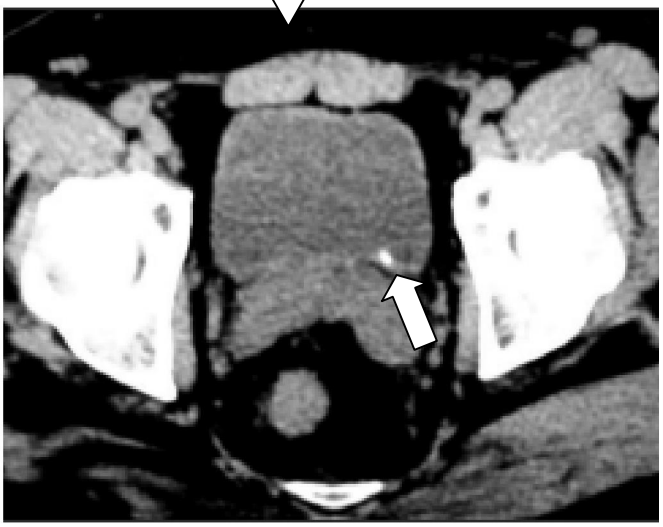

CTU: distal ureteric stone Confirmed

Renal Neoplasm:

Bladder carcinoma

IVU of a patient with hematuria clearly shows a large, irregular filling defect within the bladder caused by a tumor, compared to the normal bladder seen in the right image

Pelvic CT scan showing a **large tumor mas**s involving

the right side of the urinary bladder representing vesical

Congenital lesions

- Absent & hypo plastic kidney
- Duplex kidney and ureter
- Ectopic kidney
- Horseshoe kidney
- PUJ obstruction
- Uretroceles
- Bladder diverticulum

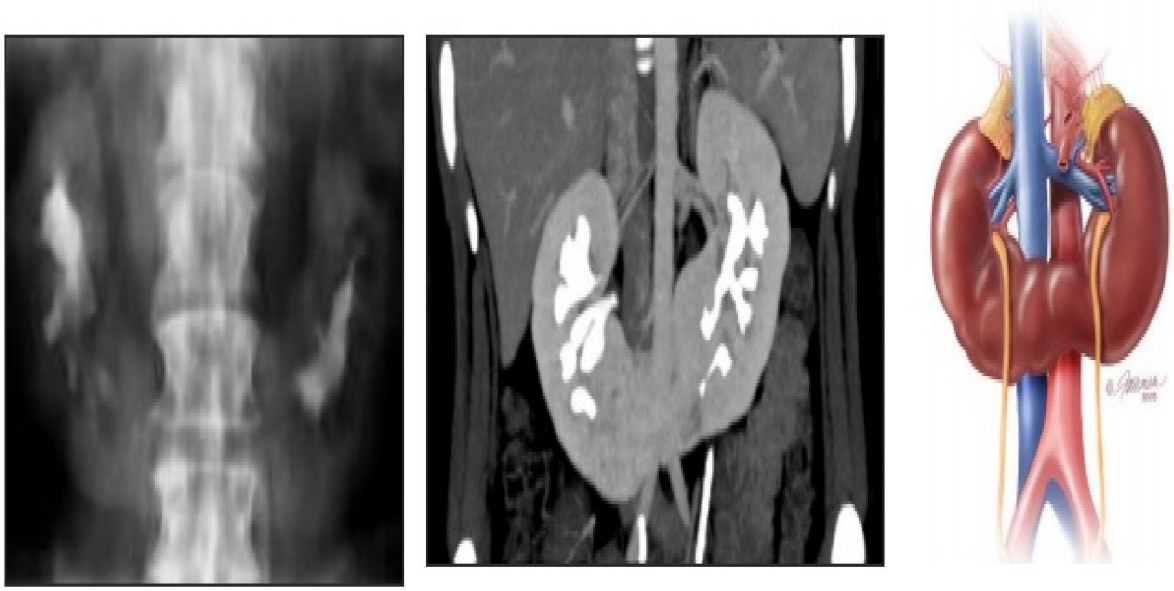

IVP and coronal reconstructed CT image showing horse- shoe kidney

How to choose Modality for UT Cases

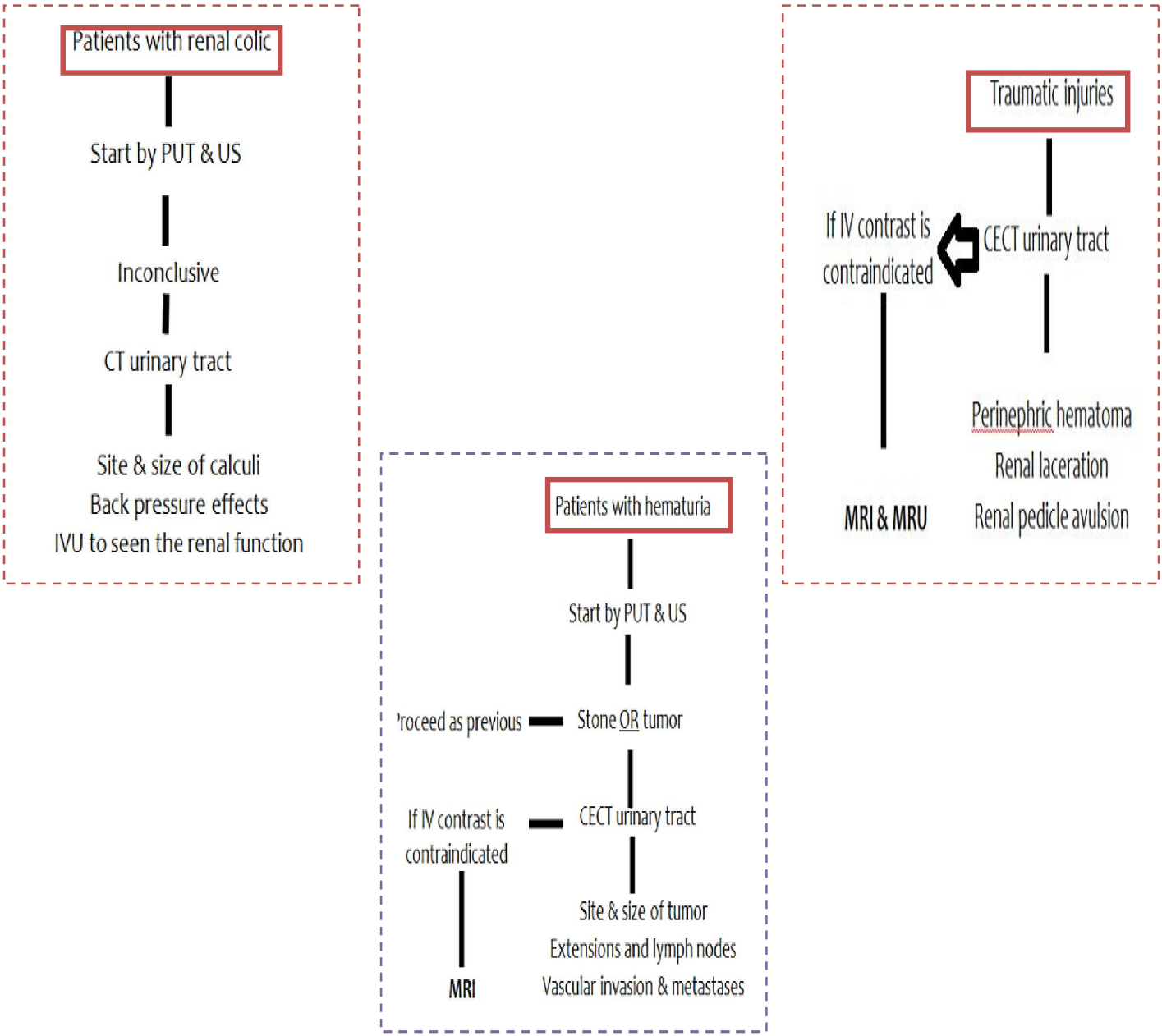

Basics of Emergency Imaging

Emergency

Serious, unexpected, and often dangerous situation requiring immediate action.

✍ Emergency Imaging :

- **Ultrasonography (US)**
- **Plain X ray**
- **Computed tomography (CT) scan**
- **Magnetic resonance imaging (MRI) scan**
- **Nuclear medicine**
- **More invasive tests**

✍ Emergency cases need imaging assessment may be :

- **Traumatic :** Fractures, organ injury , bleeding
- **Inflammatory:** as meningitis, Abscess, Peritonitis, Appendicitis ….etc.
- **Obstructive :** as Hydrocephalus , intestinal obstruction, hydroneprosis, ischemic …… etc
- **Hemorrhagic :** internal hemorrhage

…….. & others.

TRAUMA IMAGING

Fracture: bone break

Imaging:

- **X ray** : basic & initial
- **CT** :

For detailed assessment

& classification

On **bone window**

& **3d reformate**

CT showing fractures difficult to seen in X ray

Maxillo –facial trauma

- Fracture lines [Extent, Comminutions, displacement]
- Soft tissue injuries (orbit)
- Intracranial complications

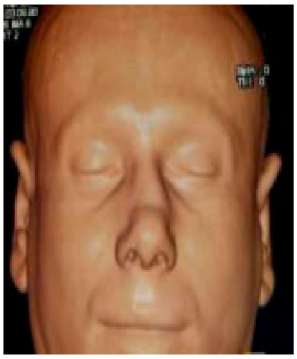

Maxillo –facial trauma Why urgent ?!

- To remove bone fragments in vital areas [orbit , brain]
- To reduce fracture before adhesions
- To release muscles before fibrosis
- To seal skull floor defects before meningitis
- To ensure patent air way
- To remove FBs before infection

Abdominal Trauma

® **Ultrasound:**

- ✓ Portable,
- ✓ rapid,
- ✓ non invasive
- ✓ Inexpensive
- ✓ No oral or IV contrast
- ✓ Serial examinations are possible

® **CT :**

- **Oral contrast** (water soluble material) → For suspected perforation
- **IV contrast** (non ionic material) :
  - Maximize the difference between the **enhancing parenchyma** and the **non enhancing hematoma** or **laceration**
  - Detect **urine extravasation**
  - Detect the **site of active bleeding**

Abdominal Pain

✓ Abdominal US:

- Initial & basic …..1st modality to use
- Can diagnose many causes as :
  - Renal or billiary obstruction
  - Intestinal obstruction & Perforation
  - Inflamatory conditions : as Acute appendicitis & its complications , Abscess
  - Organ Injury & collections

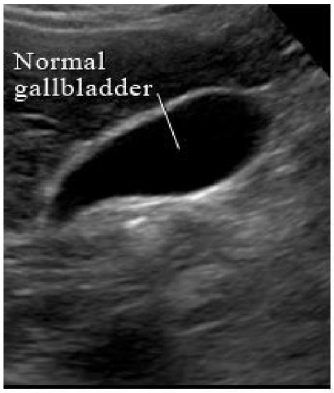

igure 1

Figure 2

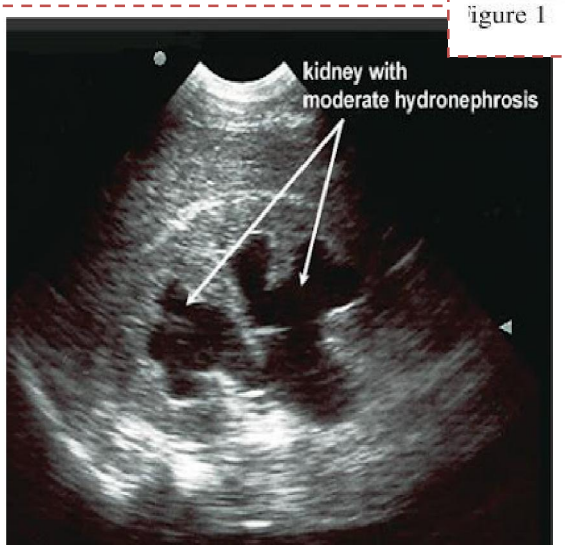

X ray Abdomen:

- **Diagnose Finding as :**
  - **Perforated gut**

    → Pneumo-peritonium
  - **Intestinal obstruction**

    → Multiple Air-fluid levels

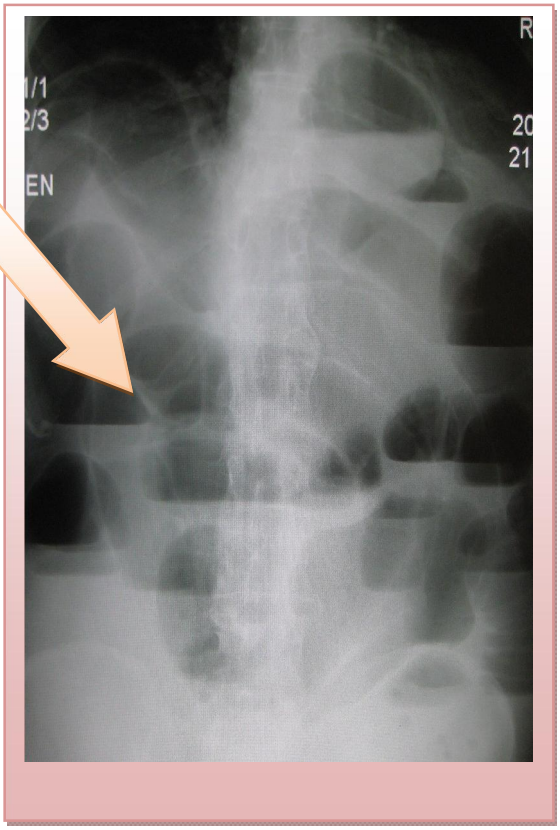

✓ **CT Abdomen :** +Oral / IV Contrast

When X ray & US

Are not enough for diagnosis

Chest Trauma

® **X ray**

For initial Assessment

® **CT**

For further & detailed assessment of

- Chest wall : Hematoma , rib fractures , surgical emphysema
- Pleura : pneumothorax
- Lung : Contusion , laceration

Rt Pneumothorax

In X ray & CT

CT Reformate 3 D Images:

Chest wall

- Fractures
- Deformities
- Neoplasms
- FB location

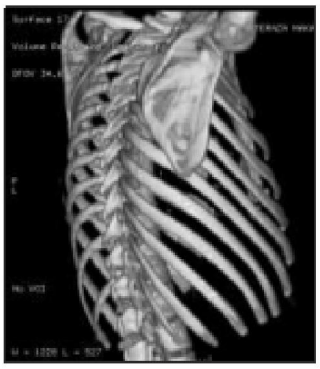

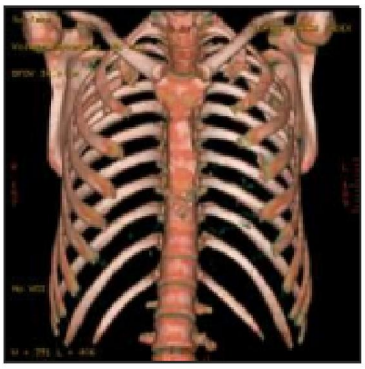

Vascular Emergency

Coronary vessels	Aorta & Mesenteric V	Limb vessels
• Occlusion • Stenosis • Anomalies • Grafts • Stents	• Occlusion • Stenosis • Aneurysms • Dissection • Leakage • Anomalies • Grafts • Stents	• Occlusion • Stenosis • False aneurysms • Dissection • Leakage
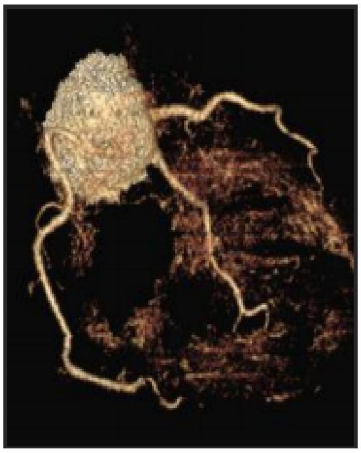		

Basics of Radiology

Interventional Techniques

Radiological Interventional procedures: minimally invasive procedures guided by imaging modalities either for diagnostic or therapeutic purposes.

Methods of guiding Interventional techniques:

- ✓ US
- ✓ Fluoroscopy (Life X ray)
- ✓ CT

Examples of Interventional techniques:

⇨ **Diagnostic :** as

- Biopsy (US ot CT guided)
- Coronary Angiography

⇨ **Therapeutic :** as

- Abscess Drainage
- Tumor ablation
- Chemoembolization
- Varicosities sclerosing Therapy
- Stenting (vessels, …..etc)
- Vena Cava filters
- Vertebroplasty

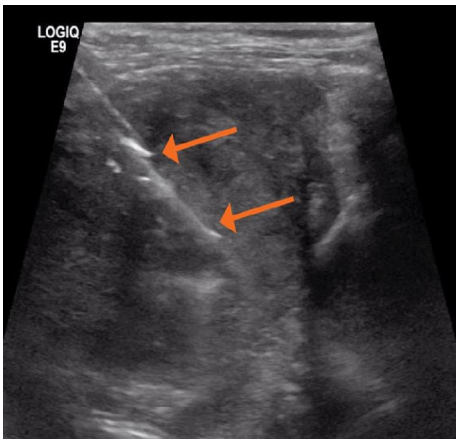

US Guided Liver Biopsy , needle is seen (Arrows)

Don't Forget:

Every Interventional Technique has its pre procedure preparation & related complications

Abscess Drainage

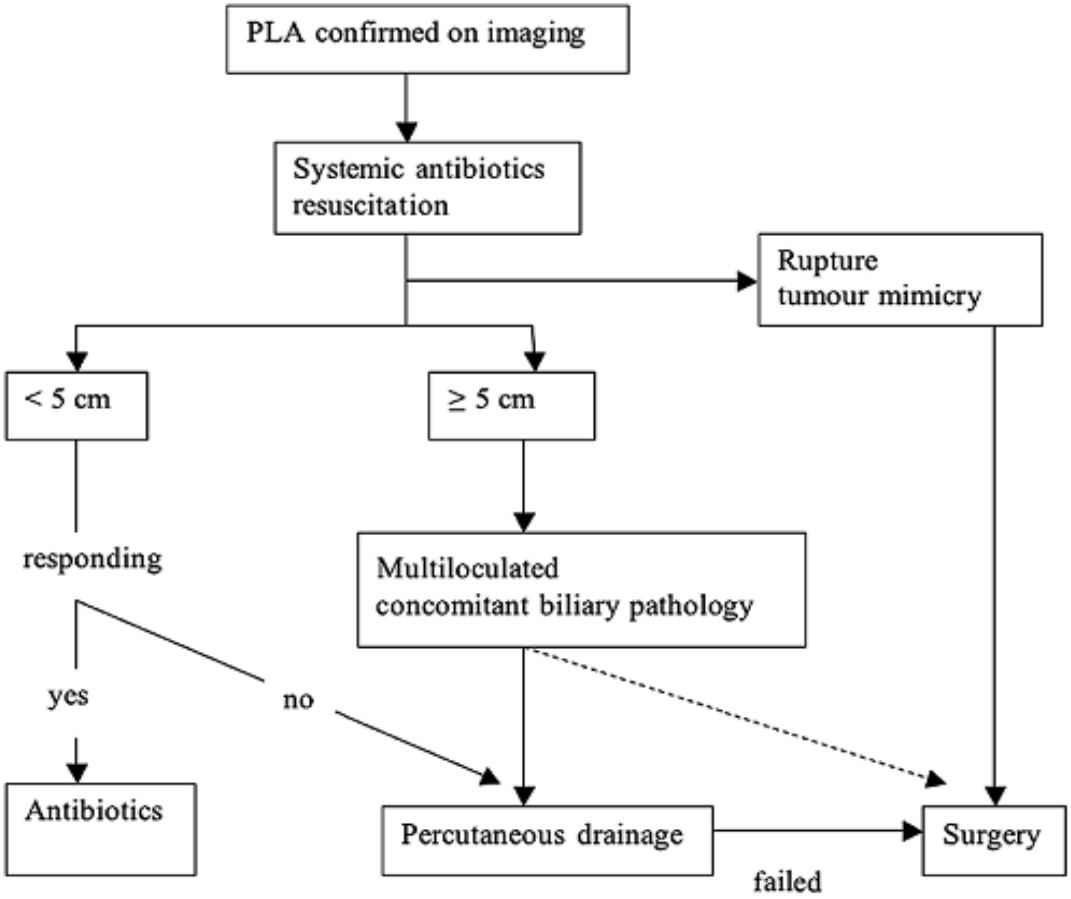

Schedule of Treating **P**yogenic **L**iver **A**bscess

Liver Abscess in US & CT

CHEMOEMBOLIZATION

Or **TACE** = **T**rans **A**rterial **C**hemo **E**mbplization

- **Definition:** A combination of local delivery of chemotherapy and embolization to treat malignant lesions, most often of the liver.
- **Role:**

Deliver a local and concentrated dose of chemotherapeutic agents directly into the arterial feeding vessels of the tumor ……**with** or **followed by** Embolization using either **permanent** or **temporary** particulate materials.

The normal liver blood supply about **75 %** through the **portal vein** and only **25 %** through the hepatic artery. ***But Hepatic Tumor receives almost all of its blood supply from the hepatic artery.***

Indications:

1 - Hepatocellular carcinoma (primary liver cancer)

2 – Hepatic Metastasis from:

- Colon cancer
- Breast cancer
- Sarcomas
- pancreatic Islet cell tumors
- ocular melanoma
- carcinoid tumors and other neuroendocrine tumors

3 - Other vascular primary tumors in the body

Contraindications :

1. Impaired liver function

N.B. **HCC when small** with good liver functions is best treated with **resection.**

Liver transplantation can eliminate the tumor and also the underlying disease.

TACE has been shown to have survival benefits in patients with **unresectable HCC.**

للاطلاع فقط

A 62-year-old man with cirrhosis and hepatocellular carcinoma (HCC) presents for transarterial chemoembolization (TACE)

Different Phases or steps of TACE Process

CT of HCC

Before & After TACE

Percutaneous Transhepatic Cholangiogram

PTC & PTD

Role:

- ✓ PTC allows visualization of the bile ducts , if they are partially or completely blocked

Indications: Evaluation of

- ✓ **Biliary obstruction**.
- ✓ **Jaundice** , which may be due to :
  - o Calcular Obstructive: CBD Stones.
  - o Malignant Obstructive: Cancer Pancreas, Duodenum, and Liver.
- ✓ **Bile Leakage**

Contraindications:

- × Bleeding Tendency.
- × Biliary tract sepsis
- × Hydatid disease

Large gallstone trapped in the duct

Vascular Embolization

Definition:

Catheter embolization is the technique of occluding a blood vessel to obtain a therapeutic effect.

GOALS

Embolization may have 3 therapeutic goals:

1. **Adjunctive goal** (eg, preoperative, adjunct to chemotherapy or radiation therapy)

2. **A curative goal** (eg, cases of aneurysms, arteriovenous fistulae [AVFs], arteriovenous malformations [AVMs], and traumatic bleeding)

3. **A palliative goal** (eg, relieving symptoms, such as large AVM, which cannot be cured by using embolotherapy alone)

Indication

- It may use Alone or Combined with surgery or radiation.

1. **Active Bleeding**
2. **Tumors Embolization**
3. **Fibroid Embolization**

Advantages: *Embolization is less invasive than surgery, this lead to:*

- ✓ **Fewer complications.**
- ✓ **Shorter hospitalization**

Uterine Fibroid, is not malignant, but may cause noisy symptoms as:

- Menorrhagia. - Pelvis or back Pain.
- Pressure on the bladder or bowel.

4. **Vascular Malformations**
5. **Aneurysms**
6. **Varicocele**

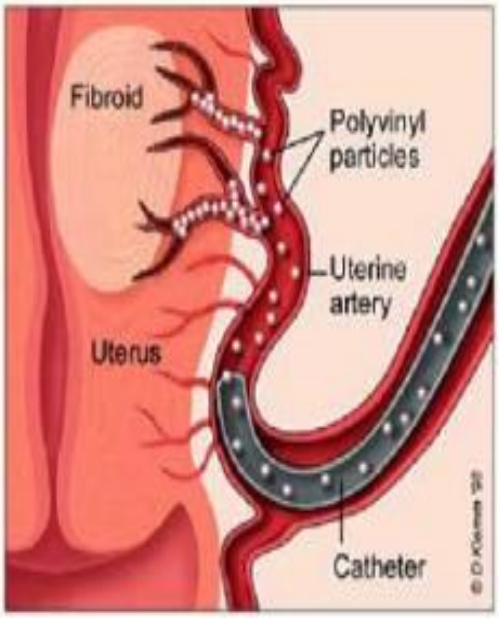

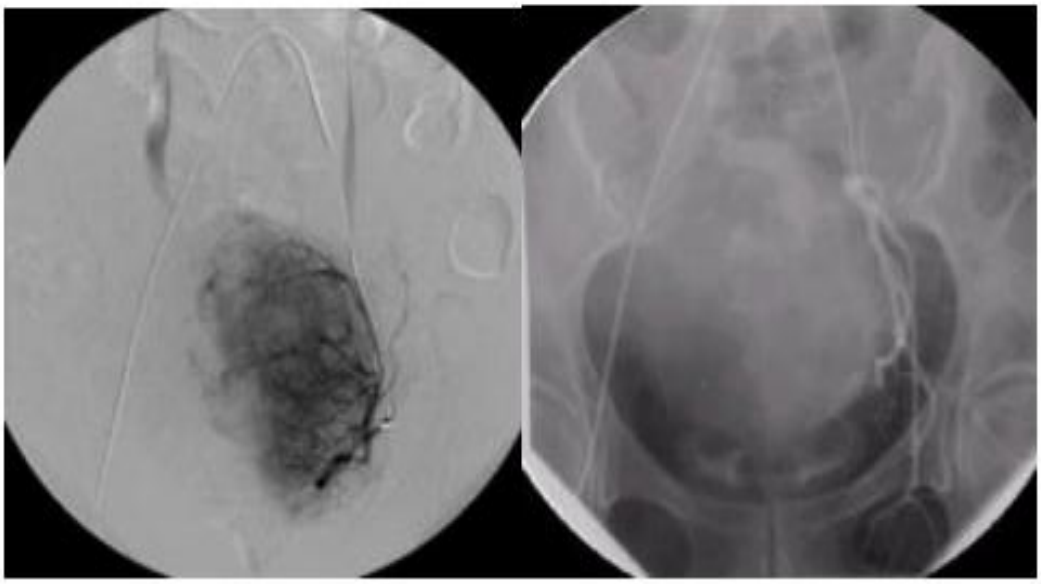

Uterine Fibroid: Pre & Post embolization

Vertebroplasty

HISTORY:

The procedure was originally developed in France in 1984 and has been further refined in the US since 1995.

Definition:

Minimally invasive procedure, in which injection of cement (methyl - ethacrylate) into a fractured vertebral body as a means of treating pain.

Aim:

To relieve pain in this patients who have not responded to conservative measures.

Pathology:

- ✓ Vertebral body fractures → Vertebral compression → pain.
- ✓ Common result of osteoporosis.

Spot Cases Atlas

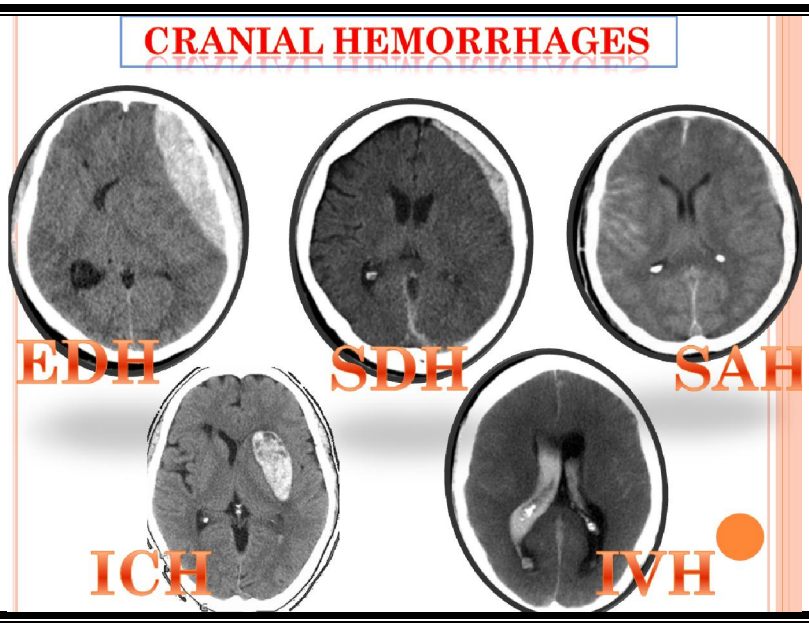

Cerebral Infarction

Acute (Days)	**Sub Acute** (Weeks)	**Chronic** (months)
+ Mass effect of edema	+ No mass effect	+ Evacu dilatation of adjacent ventricles
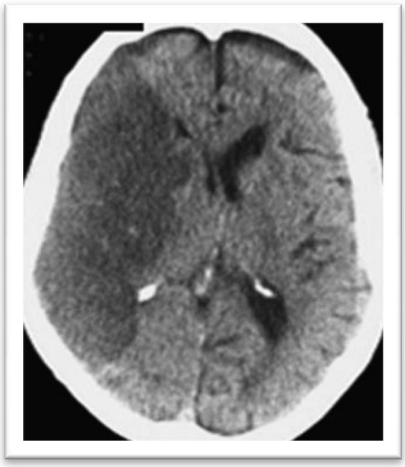	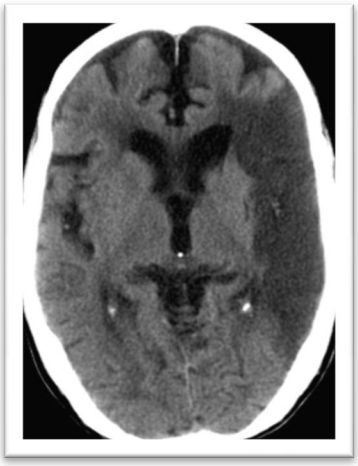	

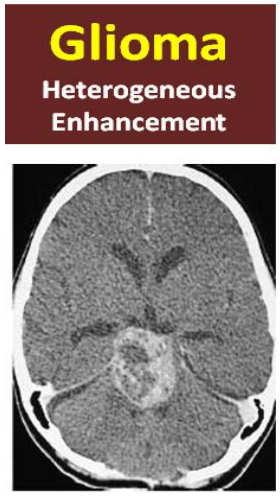

F.B. Inhalation 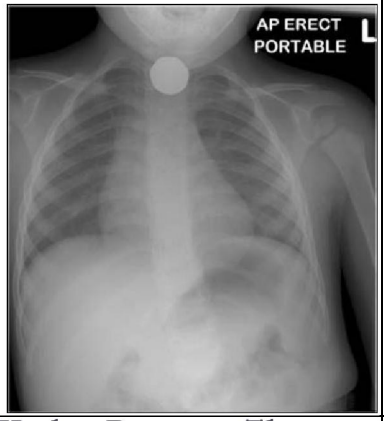	Pneumo-pericardium	Minimal Rt pleural Effusion 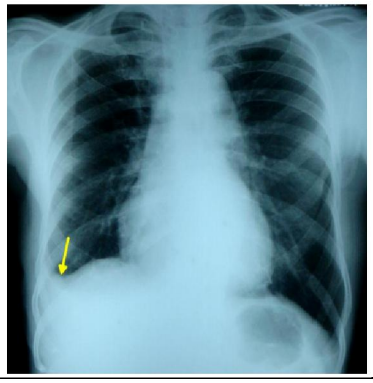
Hydro-Pneumo Thorax 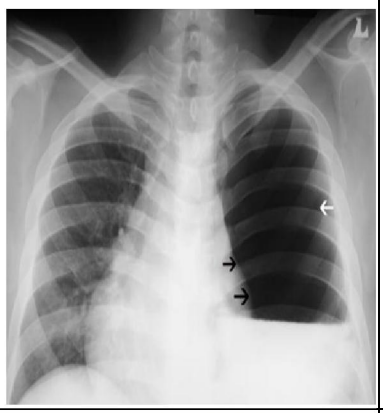	Pleural Effusion	Lung Mass
Mediastinal Mass 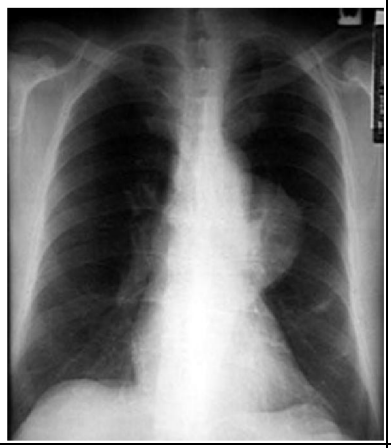	Lung Abscess	Pneumo peritoneum 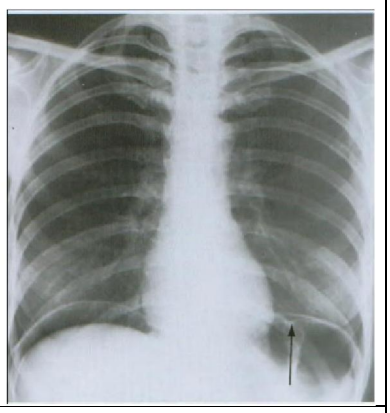

Dextrocardia

Situs Inversus Totali

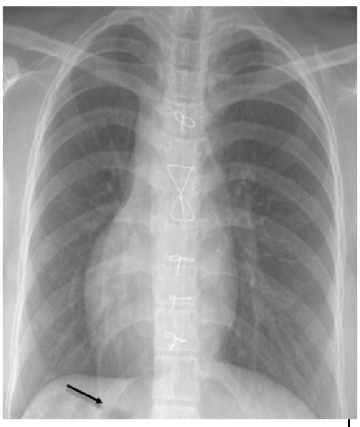

Cardiomegally

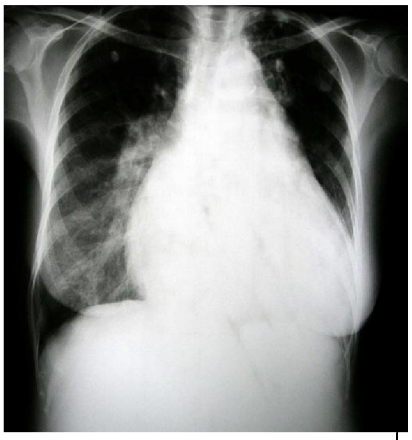

Pneumo peritoneum

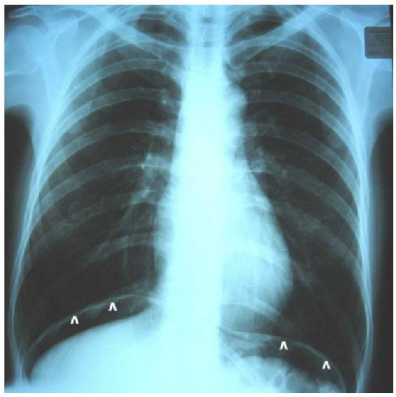

Tension Pneumothorax & lung collapse

Middle zone pneumonia & Pleural effusion

Intestinal Obstruction

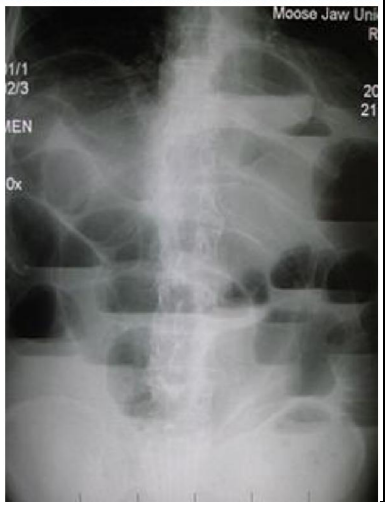

Diverticular disease

Hampton line sign Benign Peptic Ulcer

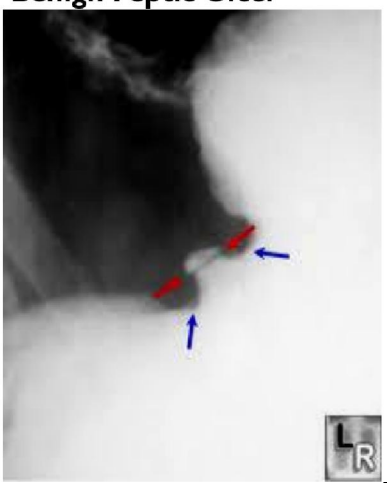

Ulcerative Colitis

Colonic malignant Stricture (Apple Core sign)

Malignant Stricture of the colon

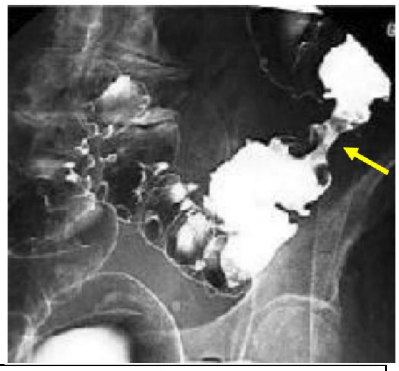

Esophageal Malignant Stricture

Hirschsprung disease

Imperforate Anus

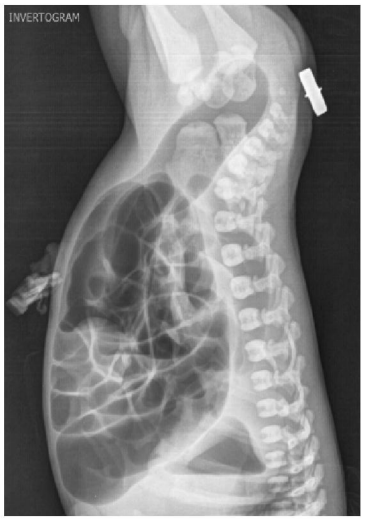

Rt Ureteric Stone

Lt Ureteric Stone

Lt Hydronephrosis & Hydroureter

Bilateral Stag horn stone

Lt Double Ureter

U.B. Mass

Lt renal stone

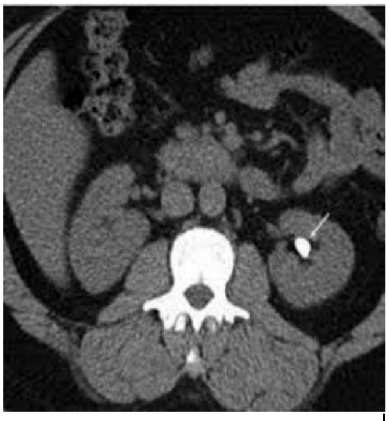

Rickets

Silver beaten sign

Green Stick Fracture

Hair on end sign

Rickets

Sources & References

- ✓ **Atlas of Human Anatomy on CT Imaging - Hariqbal Singh**
- ✓ https://www.ssregypt.com/Radiology-Handout/
- ✓ http://radiopaedia.org/
- ✓ **Summary of Chest Reporting – Prof. Mamdouh Mahfouz** , edited by A M Abodahab – MD.
- ✓ **Internal medicine | Pulmonology | Third edition** – 2015 Abdelaal | Emad M. Qasem | Asaad N. Elnakeeb
- ✓ www.learningradiology.com
- ✓ https://radiologyassistant.nl/
- ✓ https://litfl.com/normal-chest-x-ray/
- ✓ https://freemedicalmcqs.com/how-to-read-chest-x-ray/
- ✓ https://www.mayoclinic.org/